



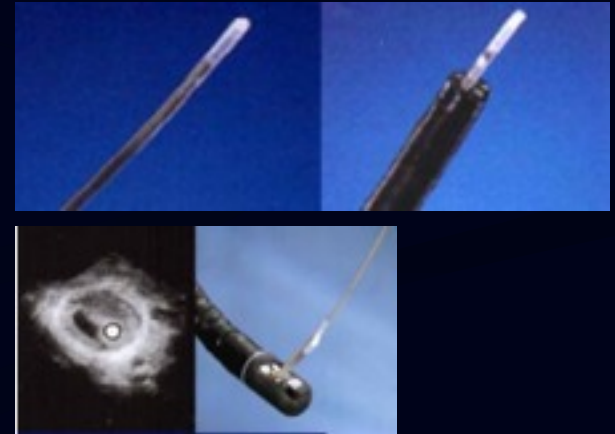ECOENDOSCOPIA DEL RETTO

Learning corner

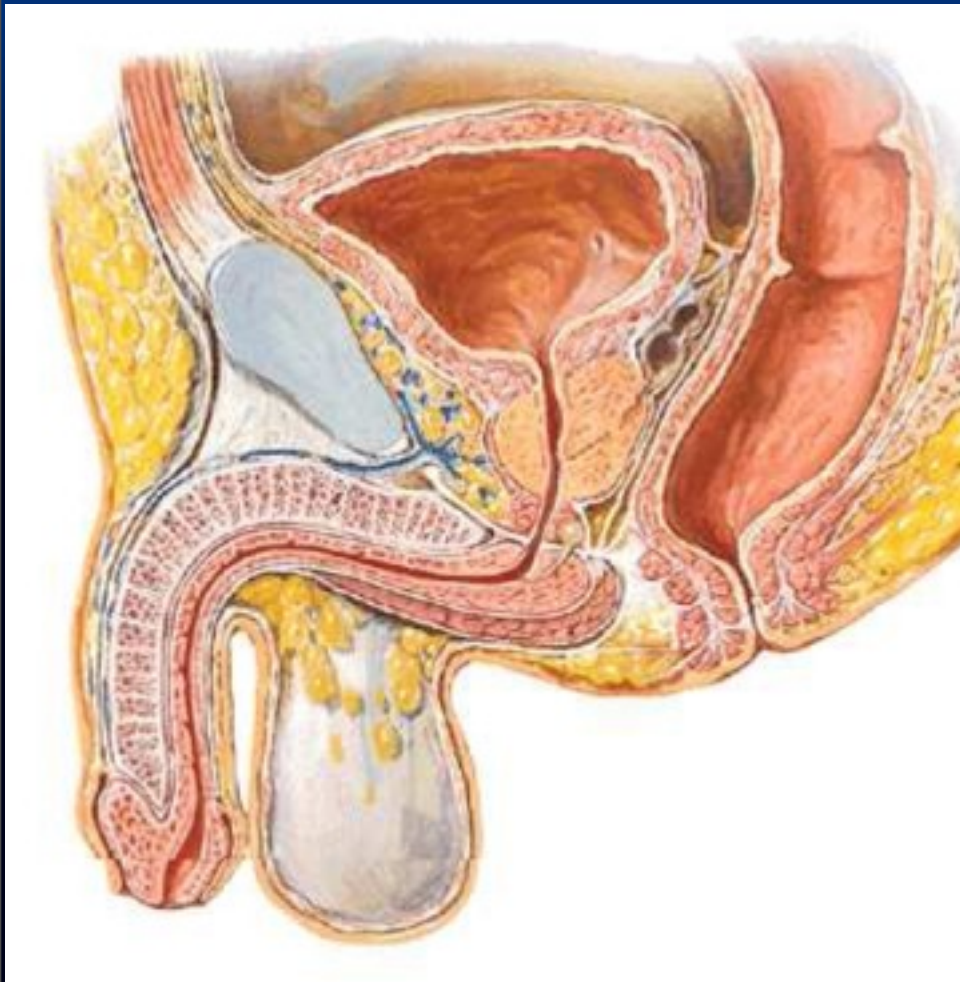**XX Congresso Nazionale delle Malattie Digestive
Napoli 19-22 Marzo 2014**

EUS RETTO: STRUMENTI

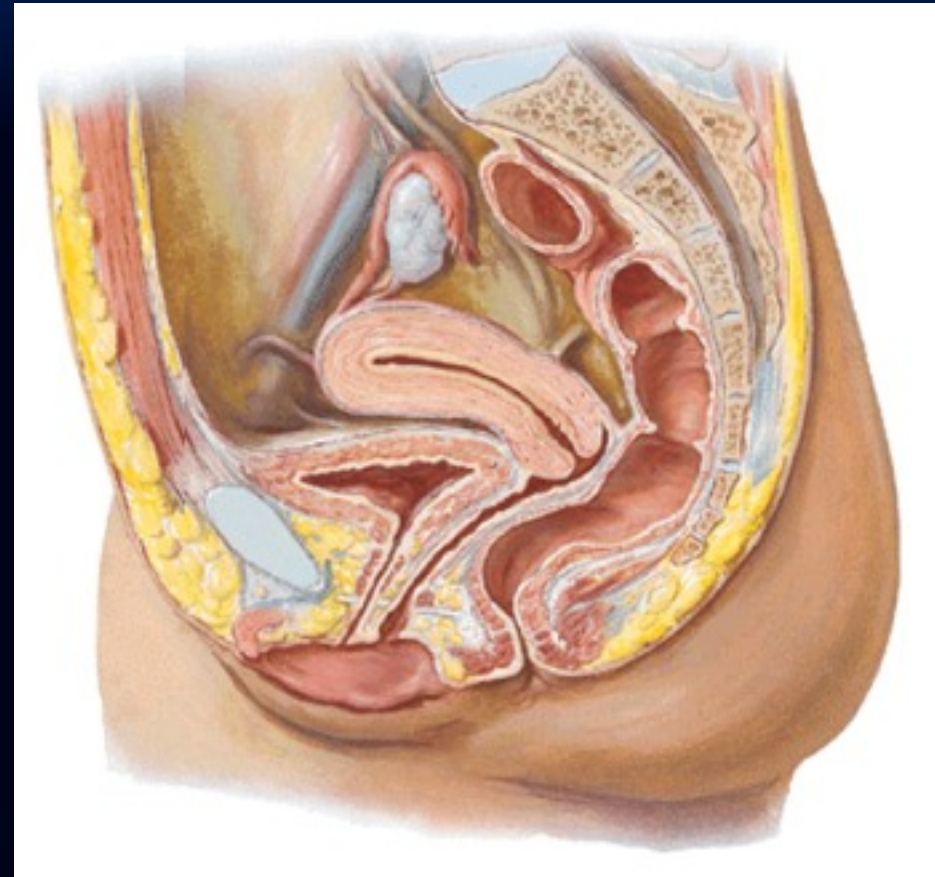
TIPO	Cieche	Visione frontale	Visione laterale-obliqua	Scansione radiale	Scansione lineare	Frequenza MHz
Sonda rigida	x			x	x	4-10
Sonda flessibile	x			x	x	7.5
Eco-endoscopi		x	x	x	x	5-20
Minisonda	x			x	x	7.5-30



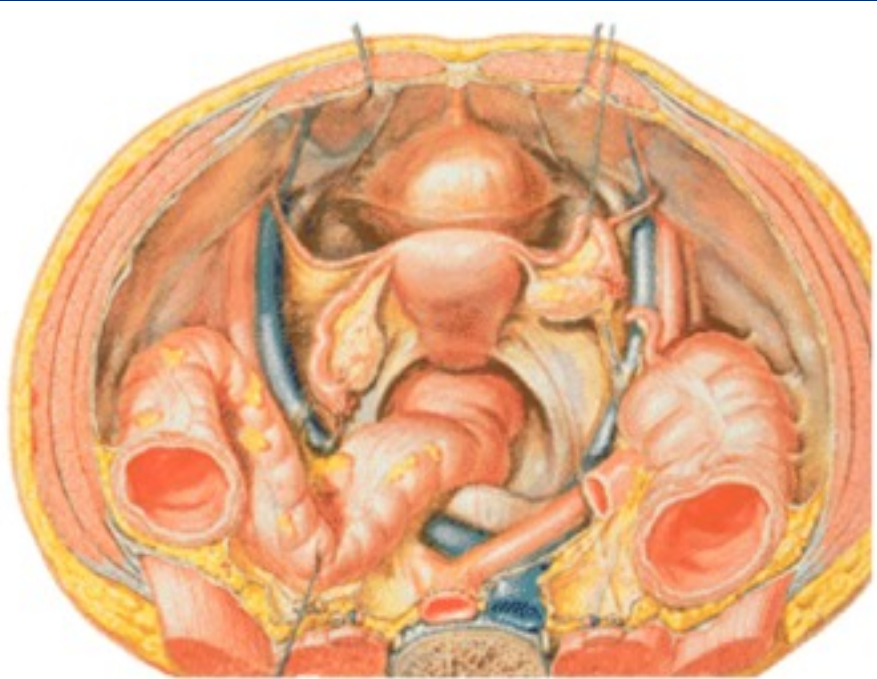
Pelvic Viscera And Perineum of Male Midsagittal Section



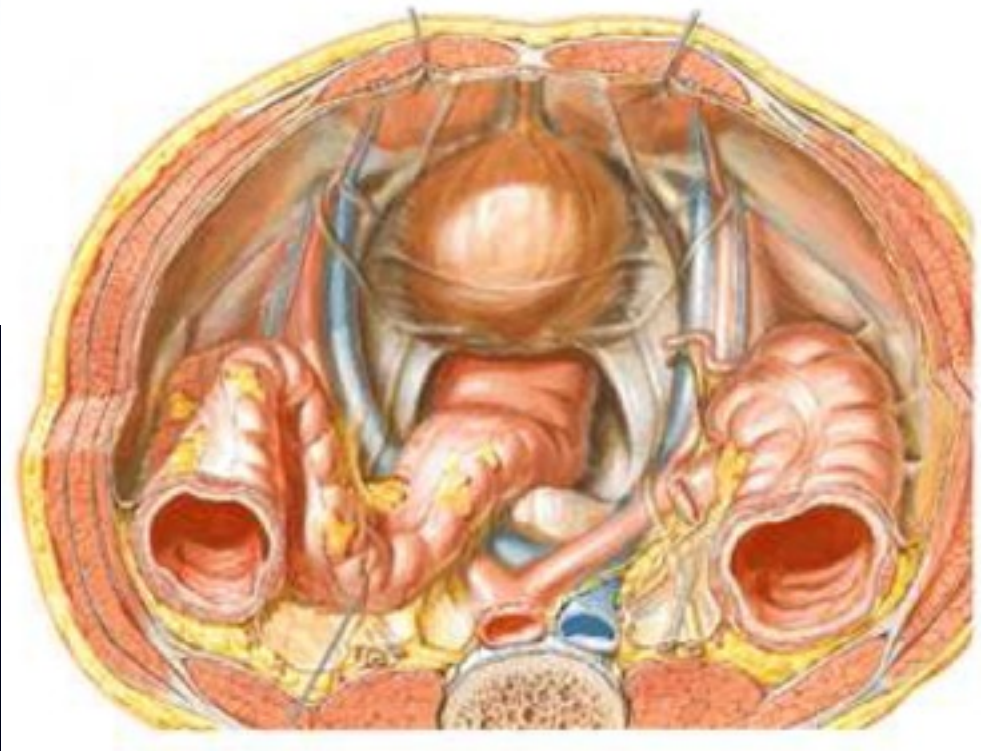
Pelvic Viscera and Perineum of Female Midsagittal Section



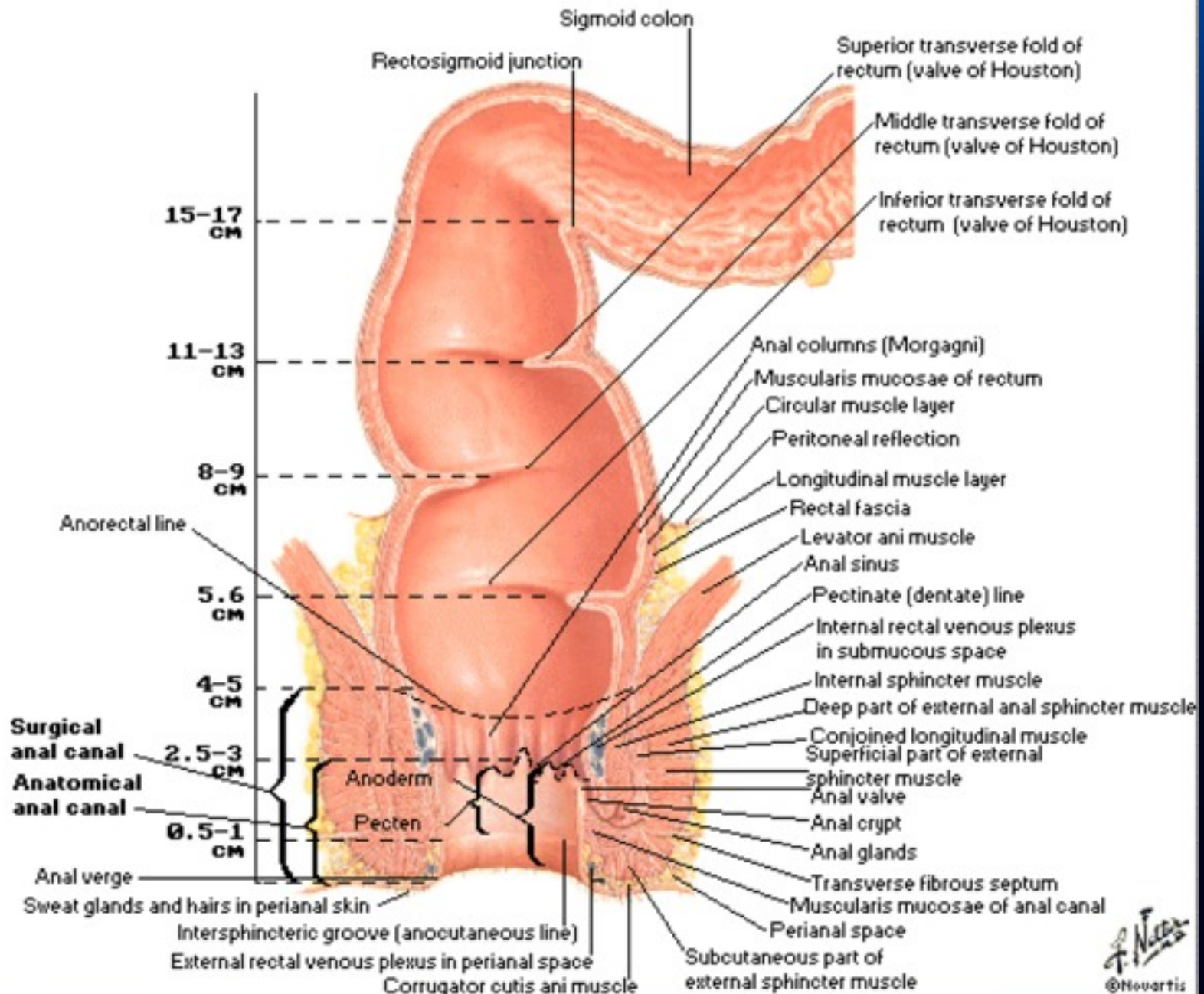
Pelvic Content of Female Superior view



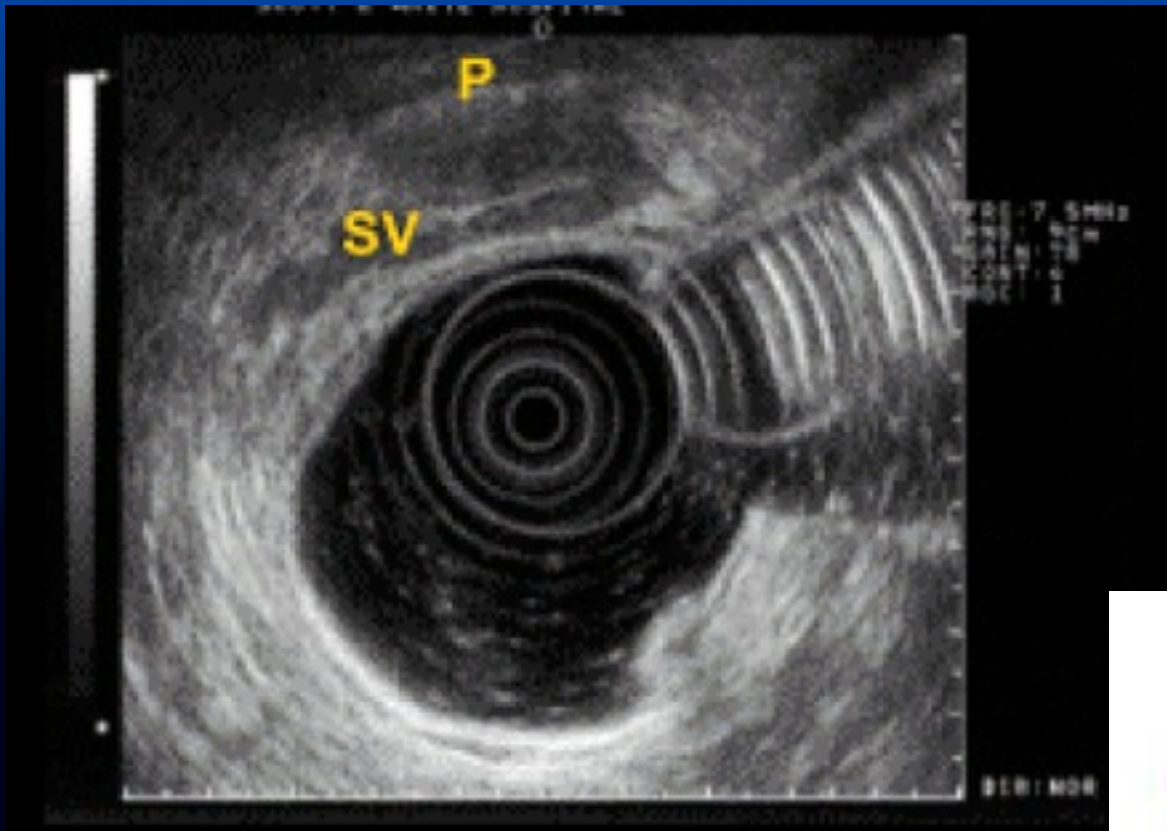
Pelvic Content of Male Superior view



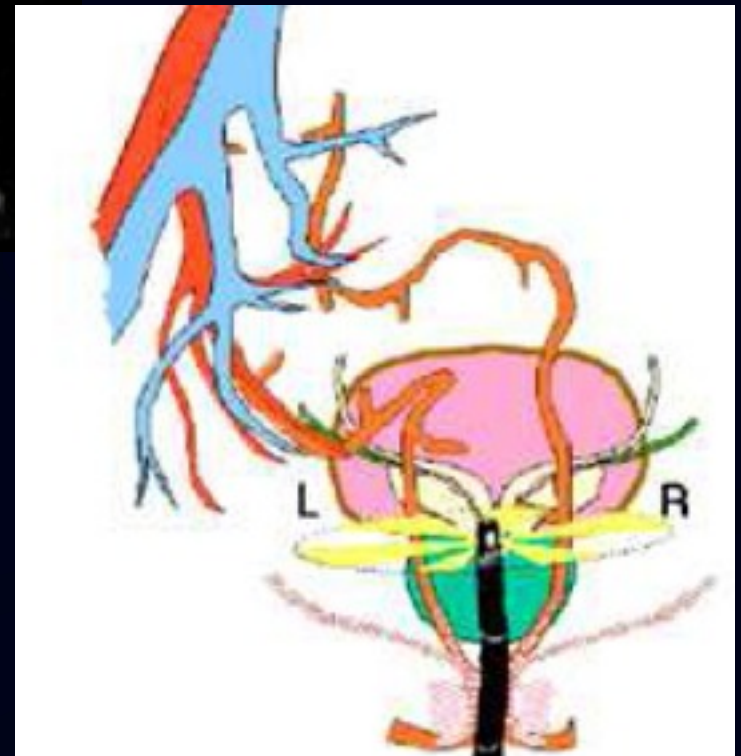
Rectum and Anal Canal

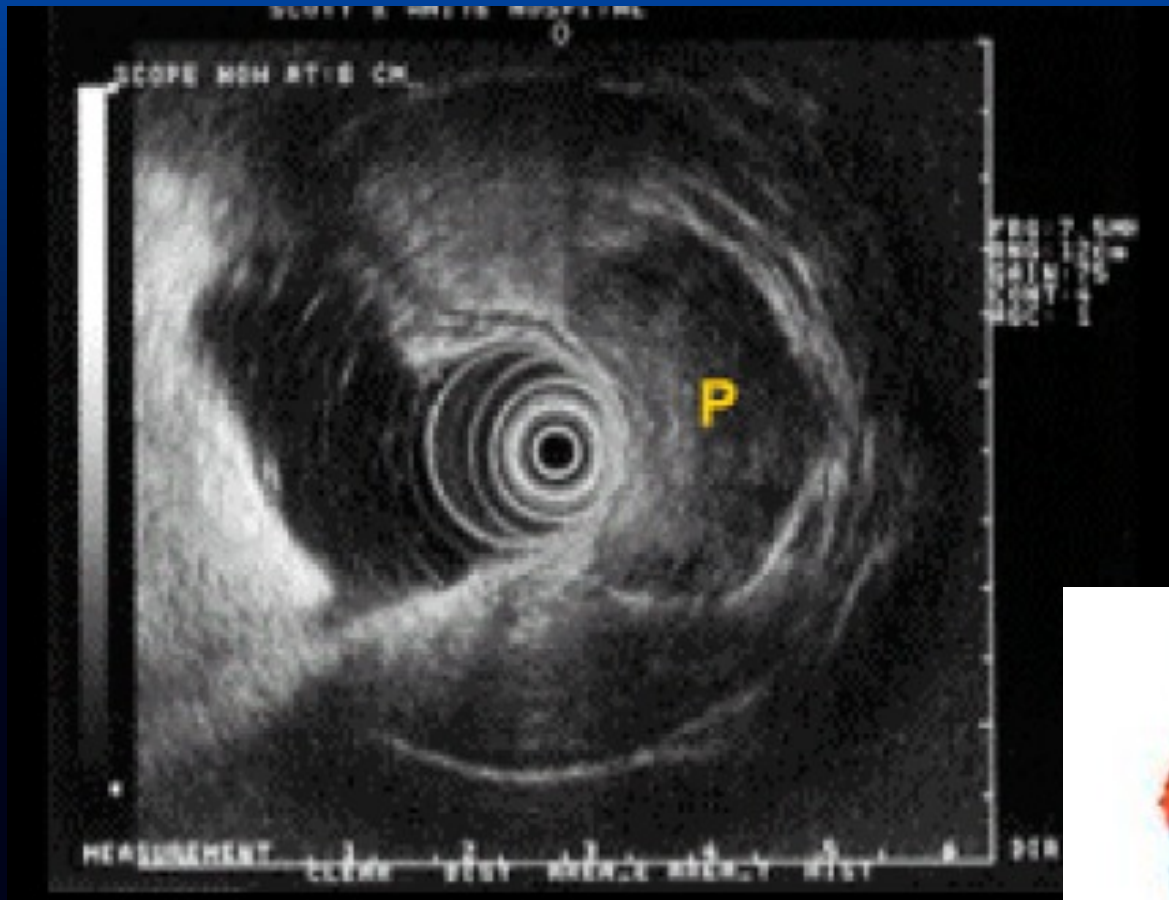


F. Nilles
©Novartis

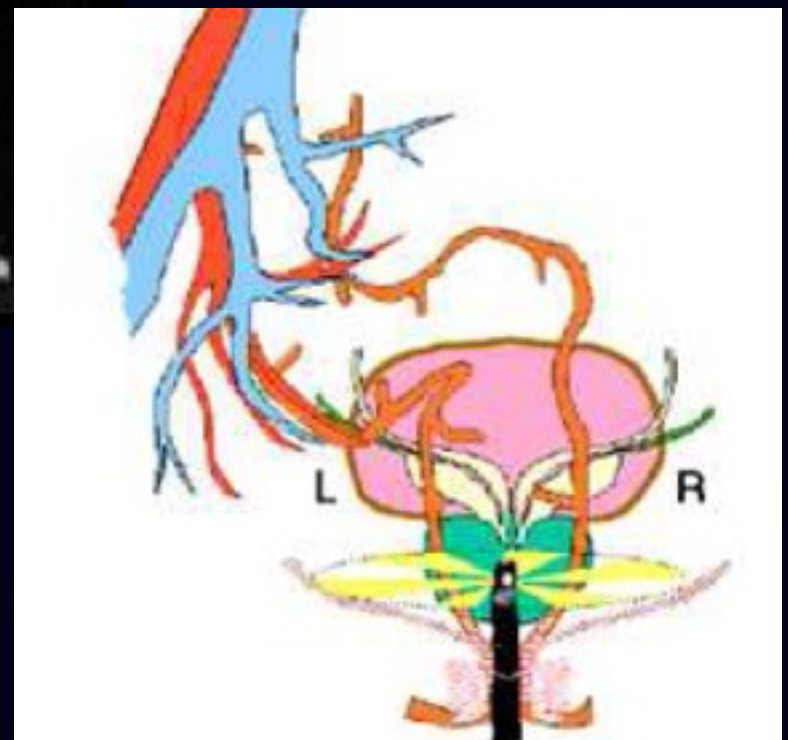


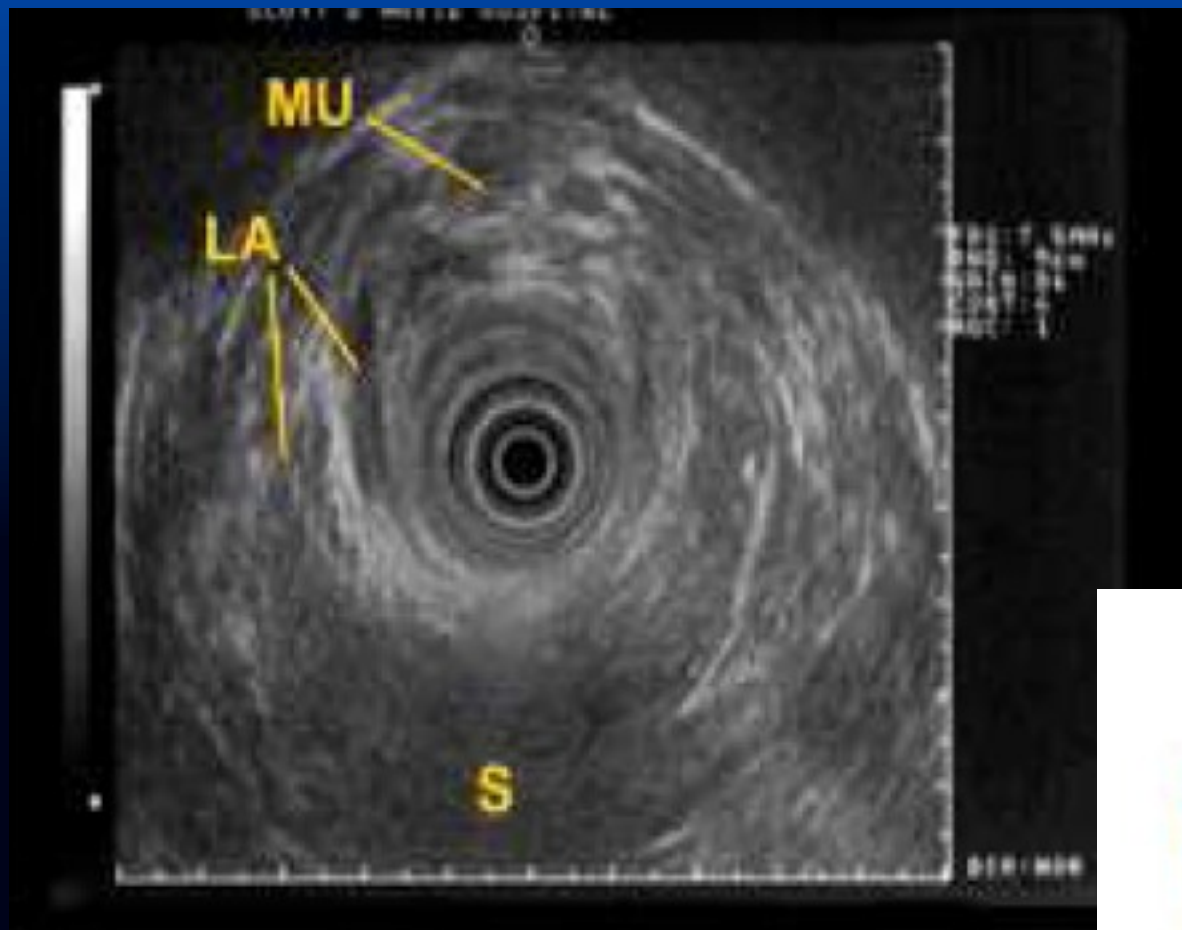
P Prostata
SV Vescichette seminali



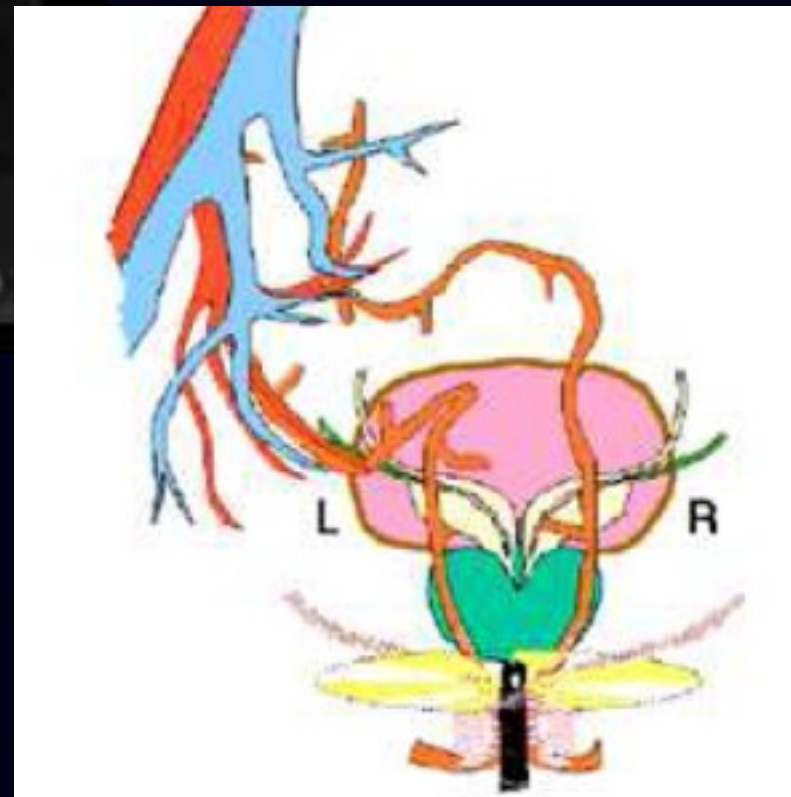


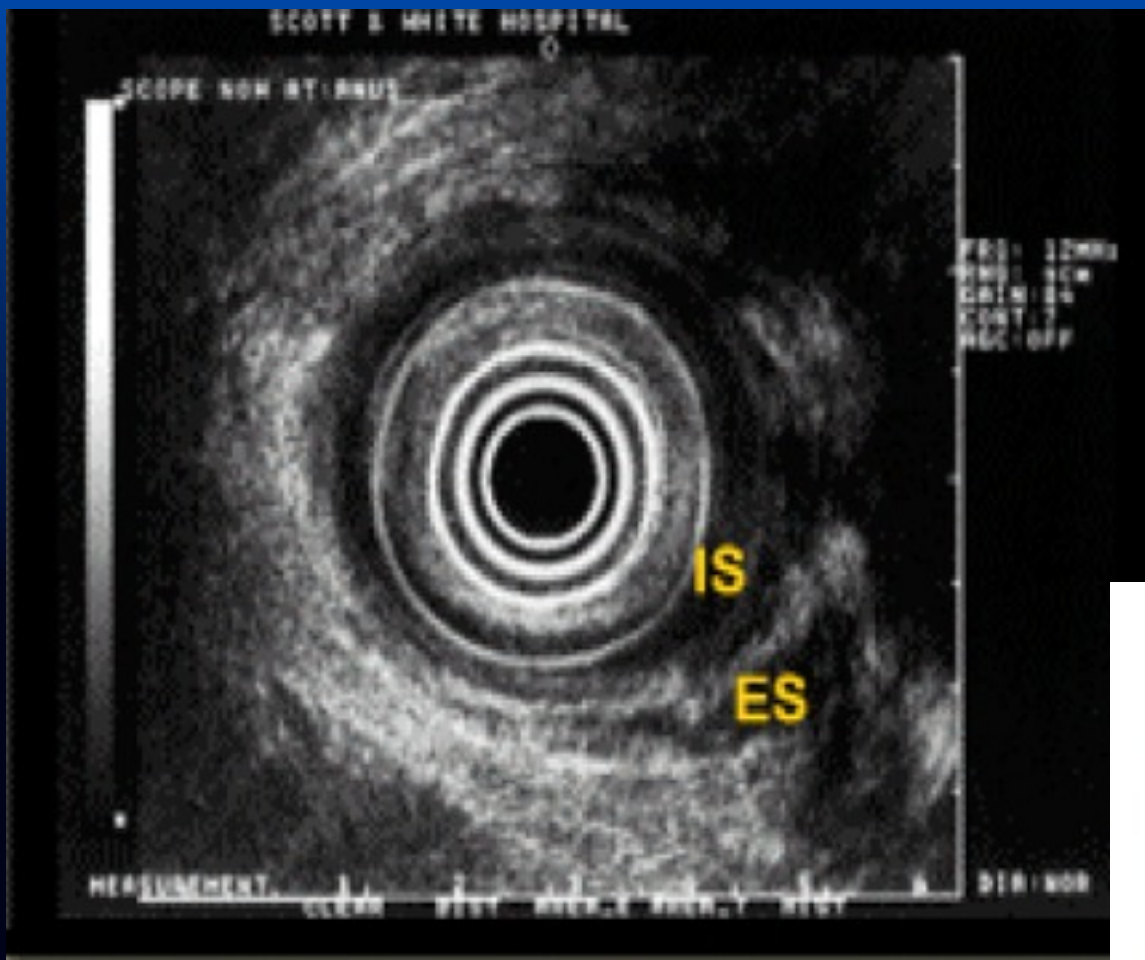
P Prostata



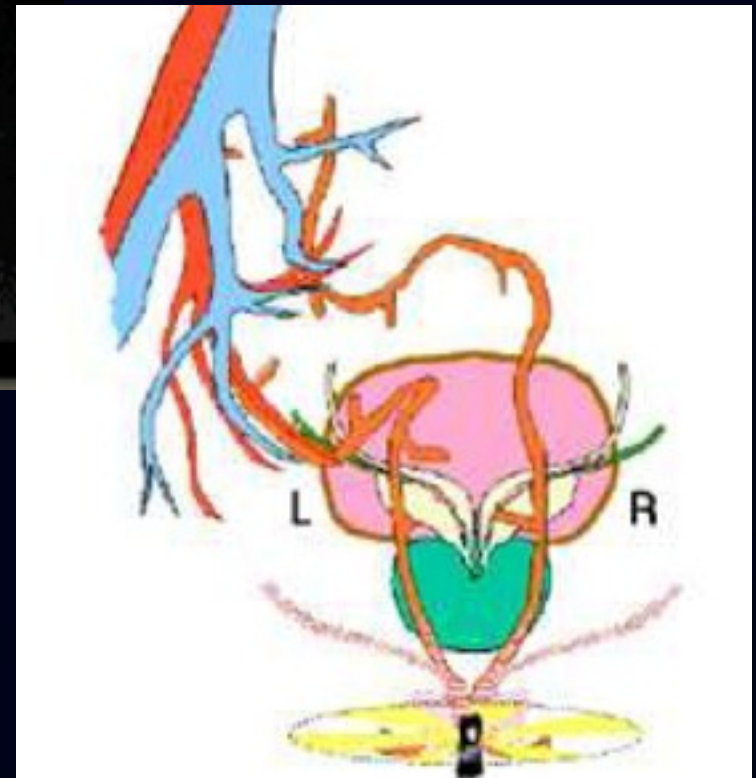


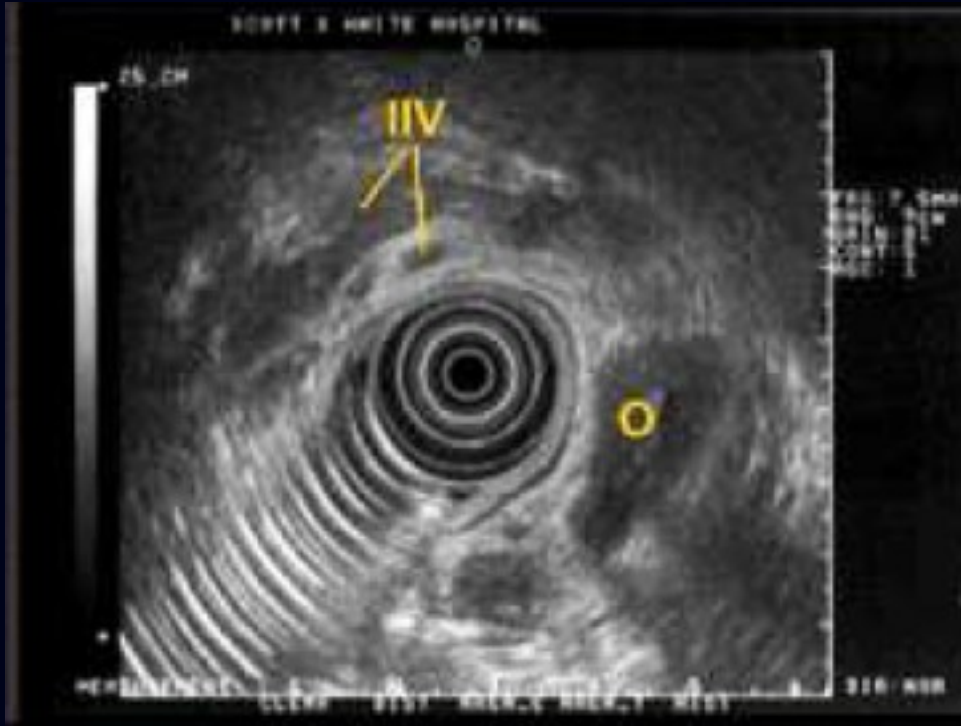
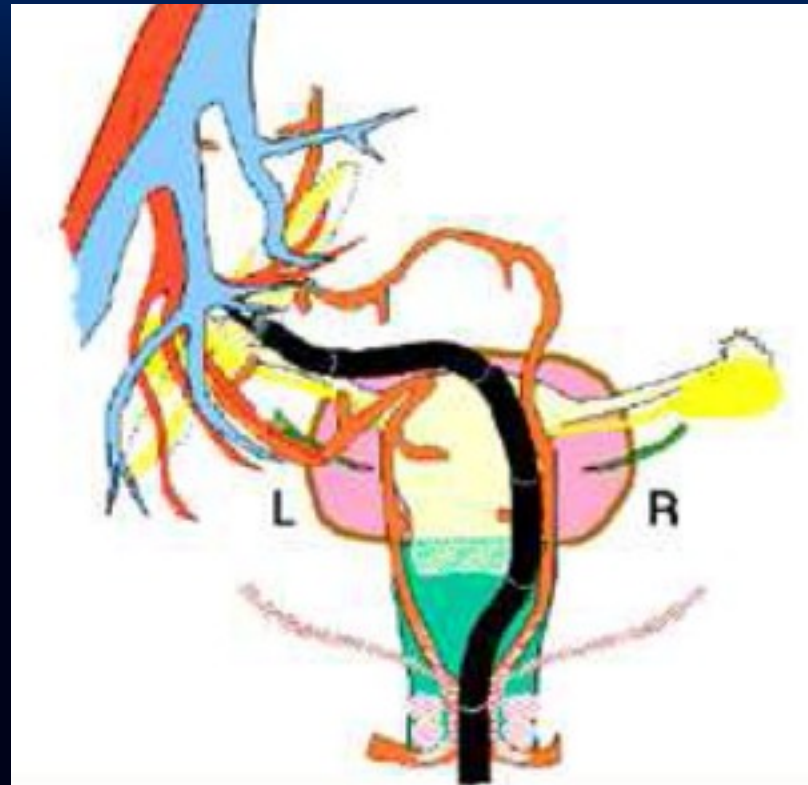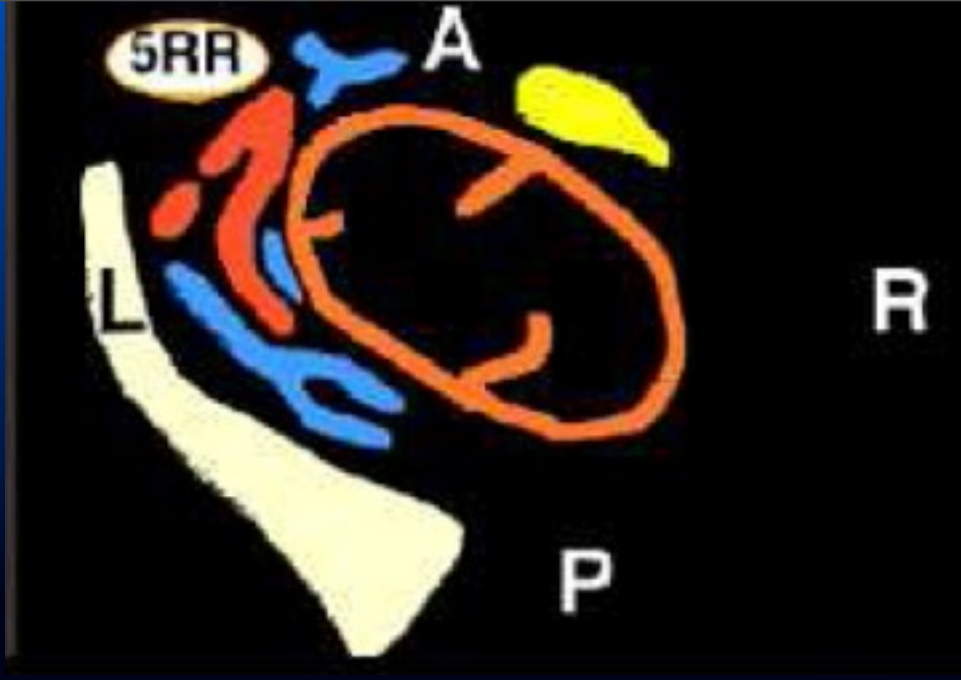
- MU** Uretra maschile
- LA** Muscolo elevatore dell'ano
- S** Osso sacro

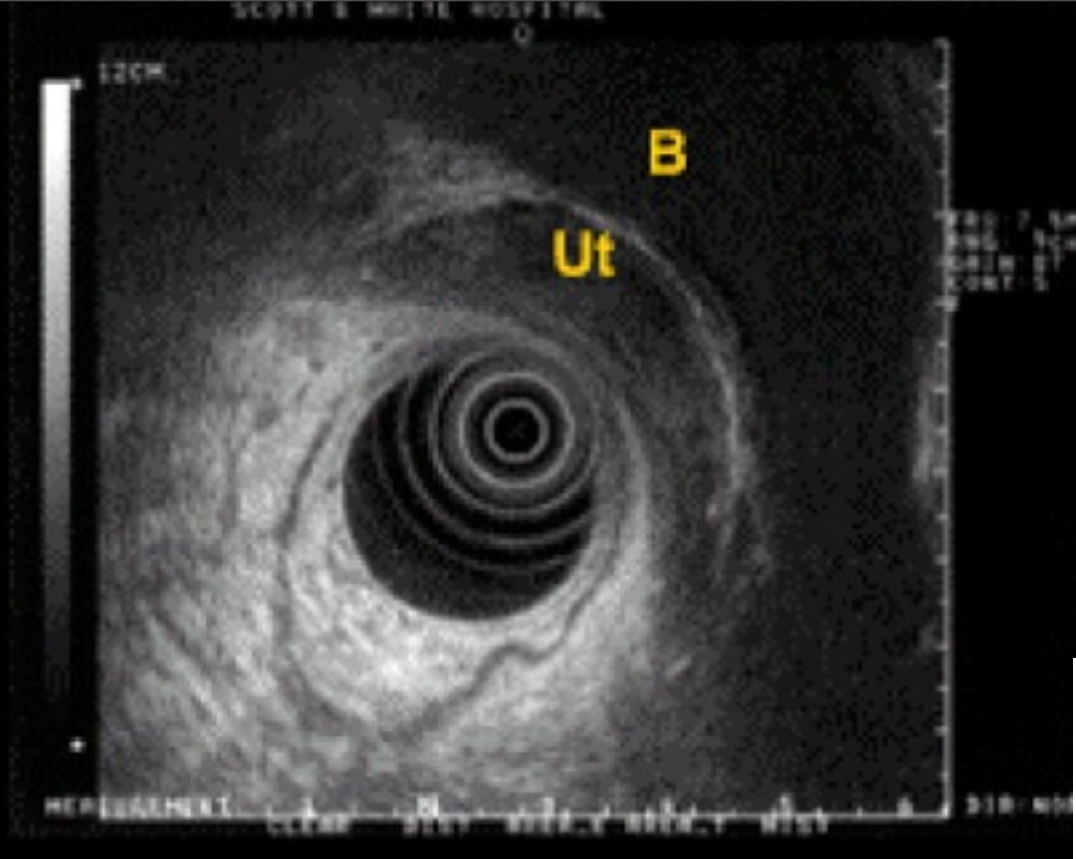



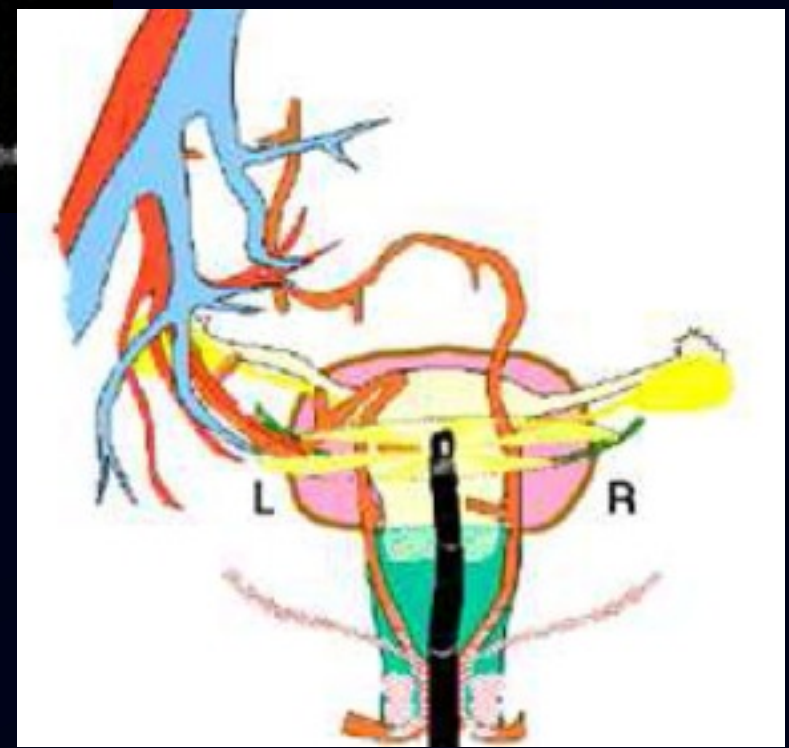
IS Sfintere interno
ES Sfintere esterno

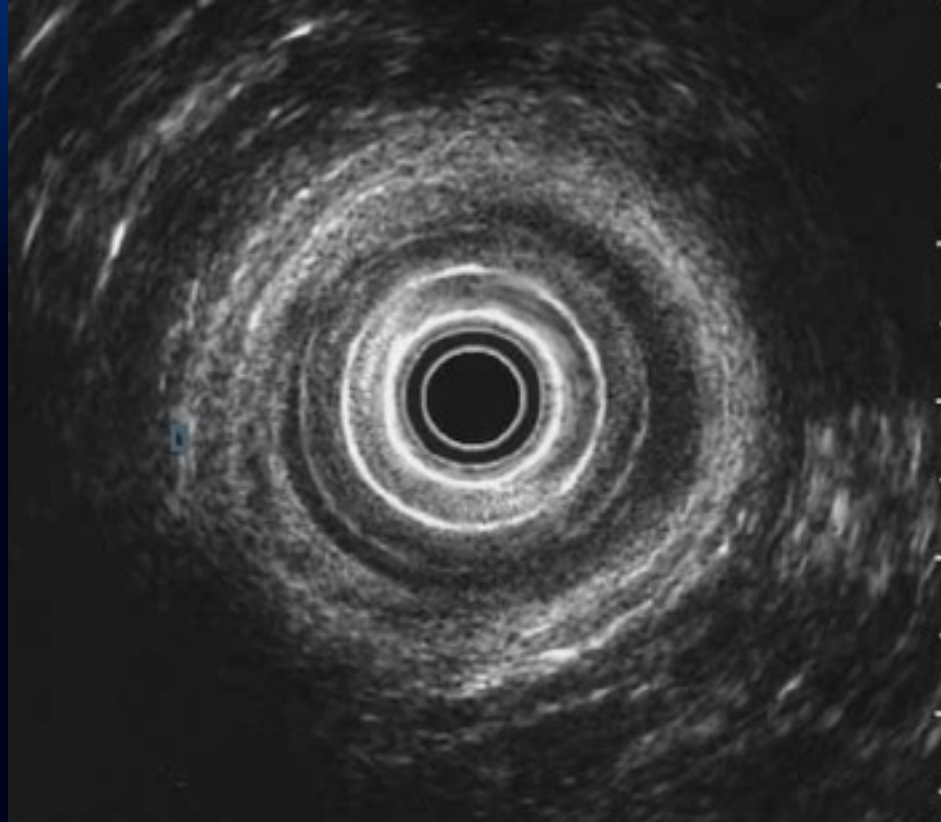






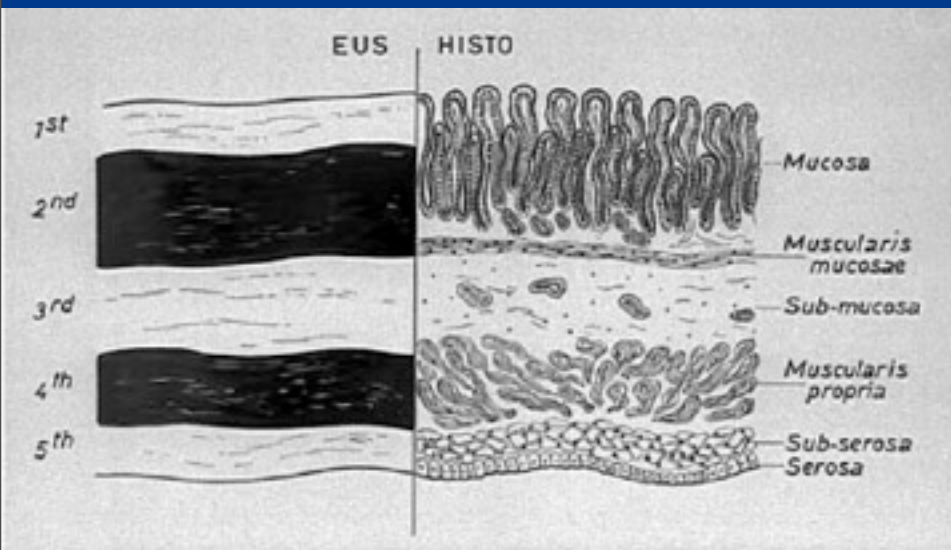
Ut Utero
B Vescica



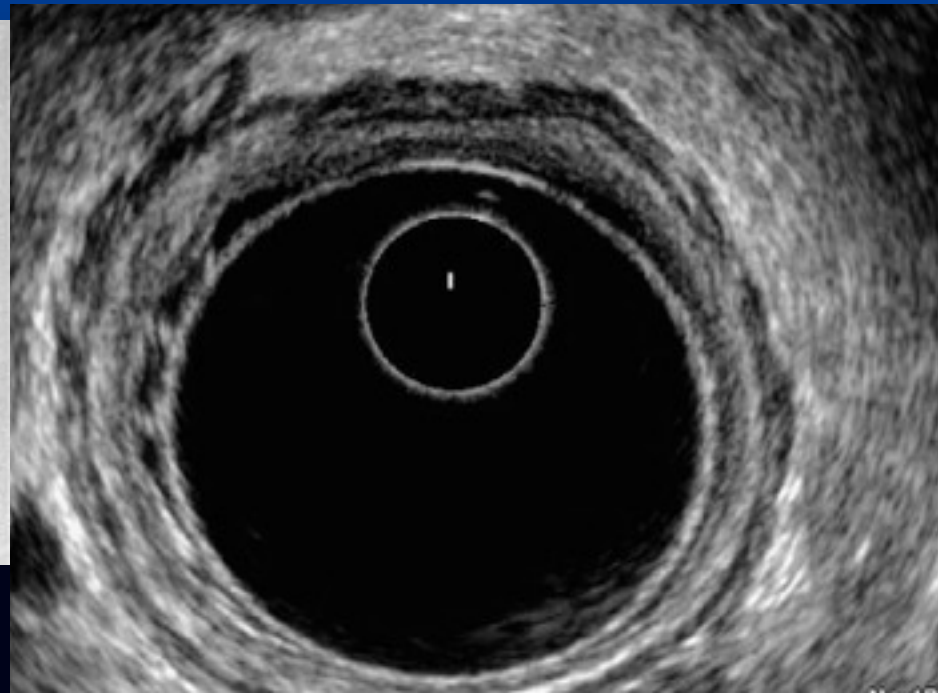
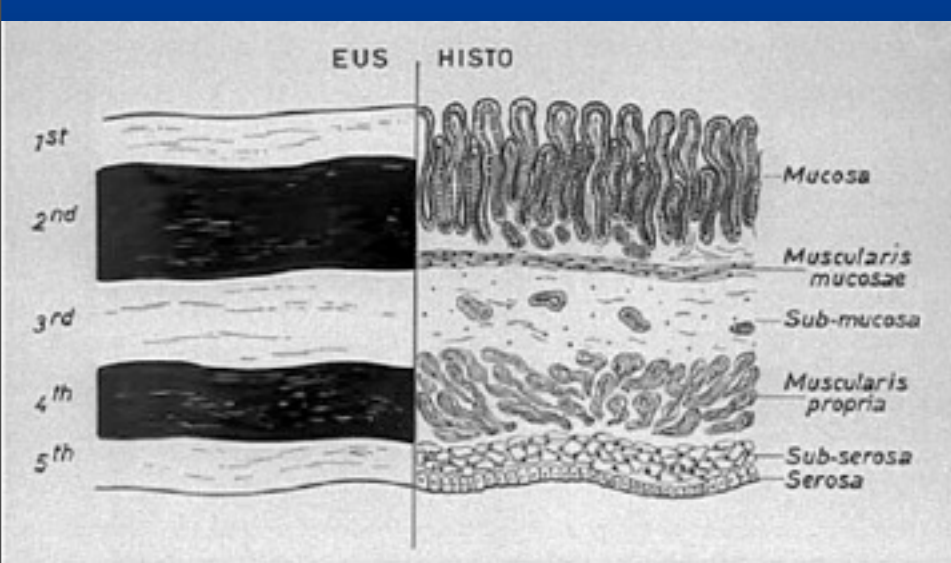


EUS RETTO: INDICAZIONI

- Stadiazione e follow-up neoplasie retto
- Lesioni sottomucose ed extraparietali (GIST, Lipomi, NET, angiomi, endometriosi, linfoma, pneumatosi cistica)
- Diagnosi e follow-up ascessi e fistole perirettali
- Patologia del canale anale



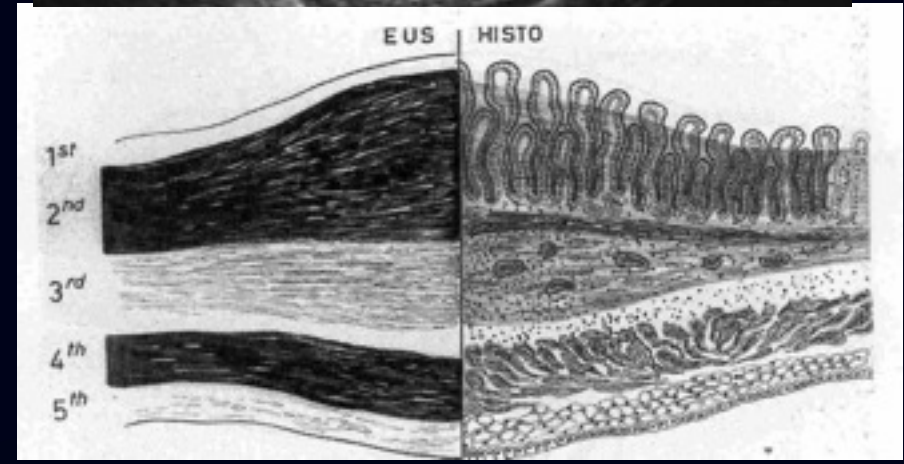
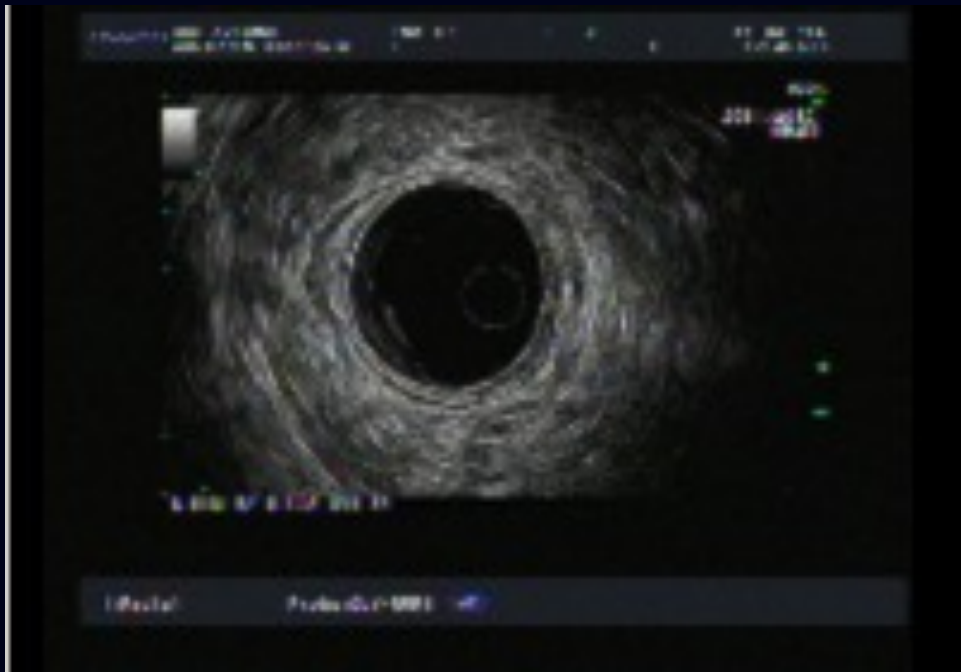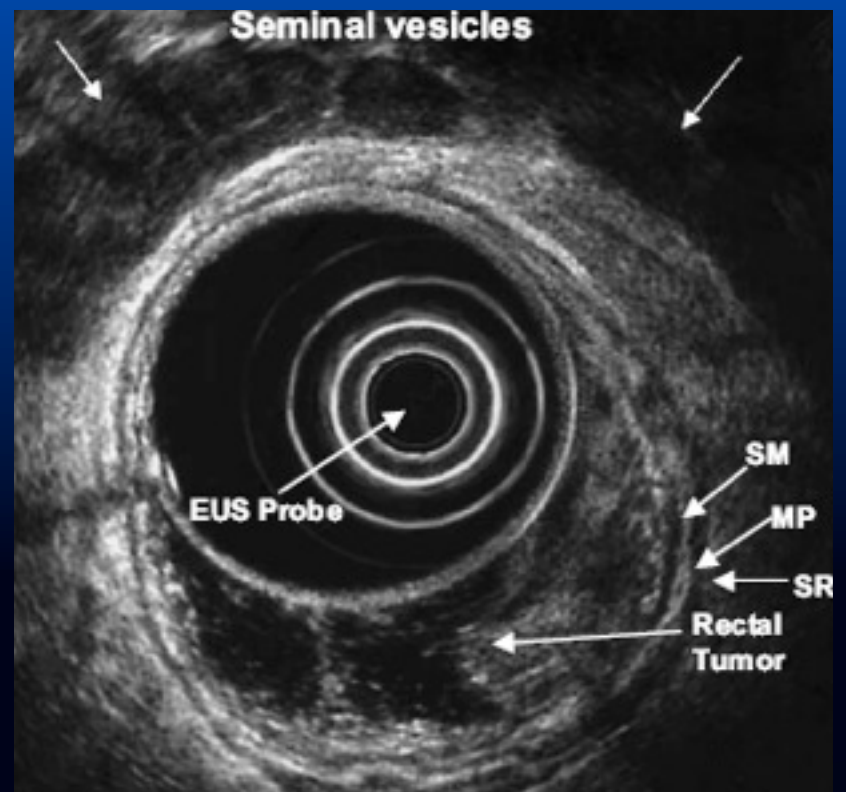
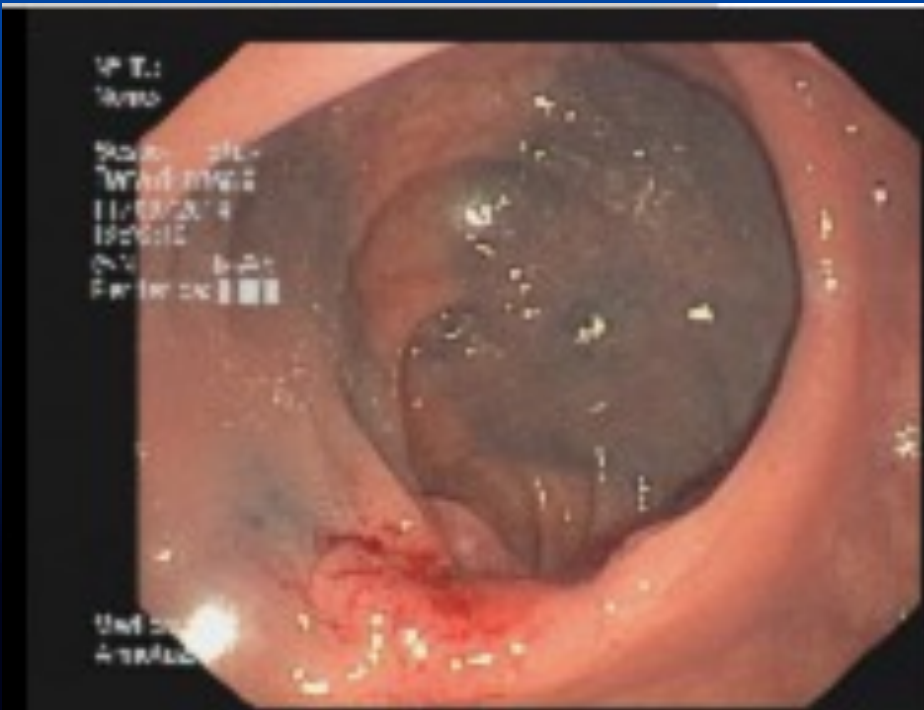- 1° strato iperecogeno: interfaccia tra acqua e mucosa
- 2° strato ipoecogeno: lamina propria e muscularis mucosae
- 3° strato iperecogeno: sottomucosa
- 4° strato ipoecogeno: muscularis propria
- 5° strato iperecogeno: interfaccia tra sierosa e grasso perirettale.



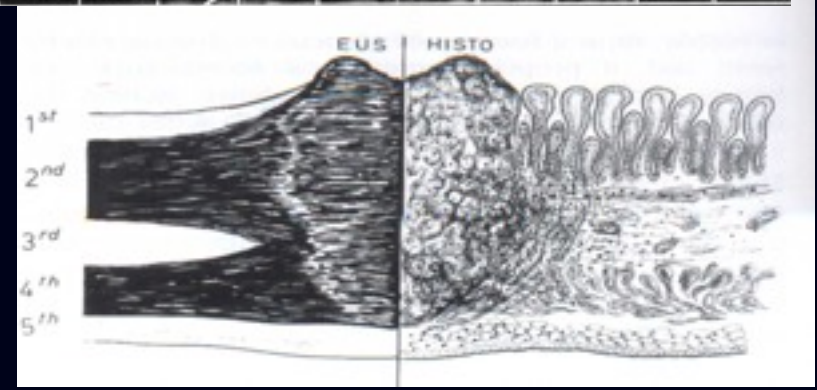
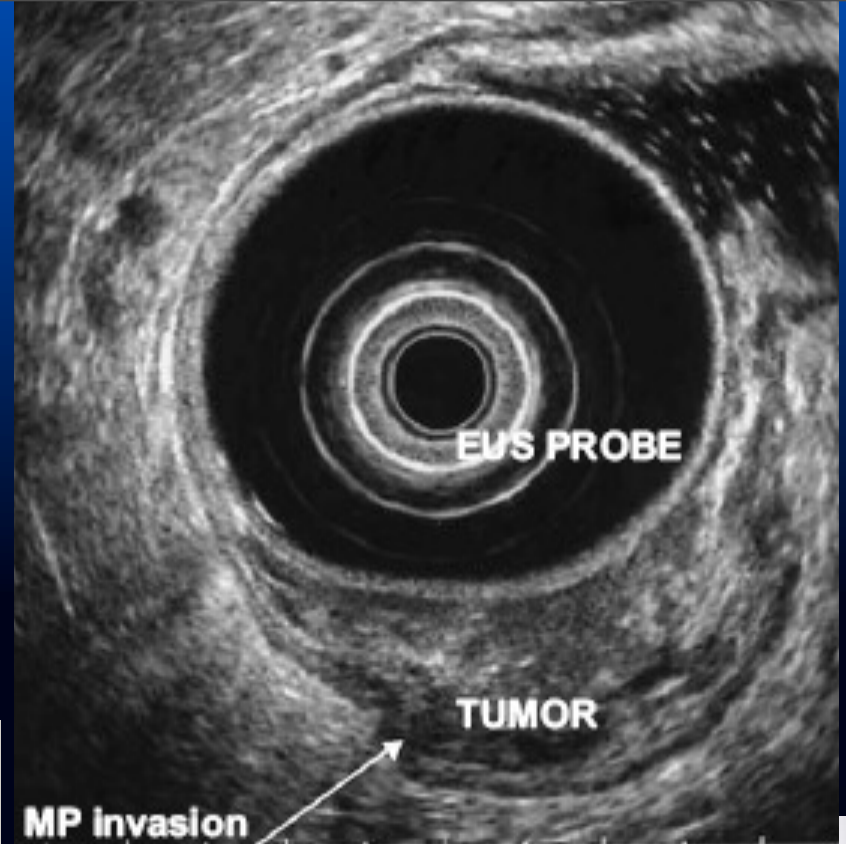
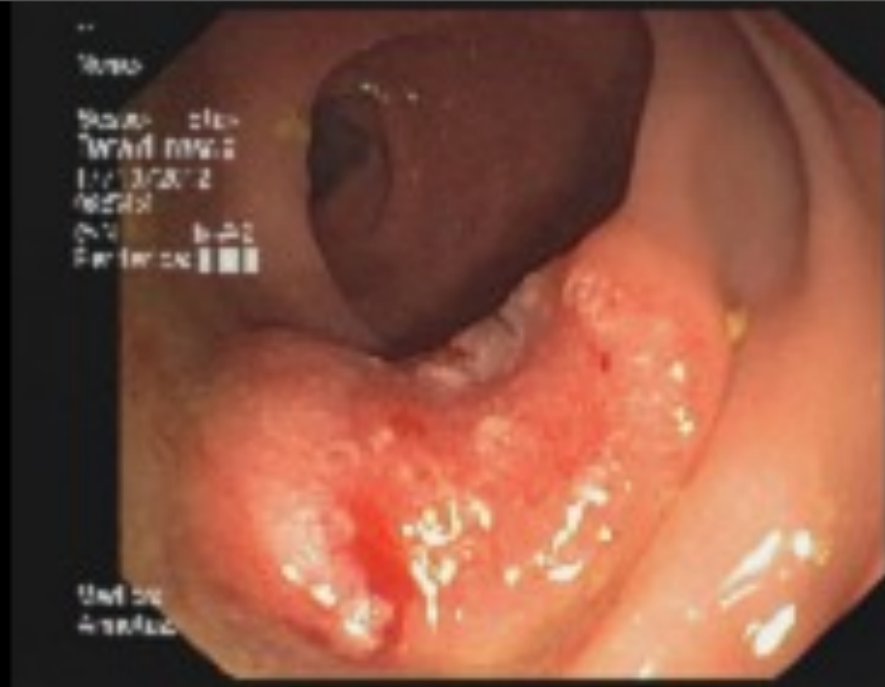
- 1° strato iperecogeno: interfaccia tra acqua e mucosa
- 2° strato ipoecogeno: lamina propria e muscularis mucosae
- 3° strato iperecogeno: sottomucosa
- 4° strato ipoecogeno: muscularis propria
- 5° strato iperecogeno: interfaccia tra sierosa e grasso perirettale.

EUS retto

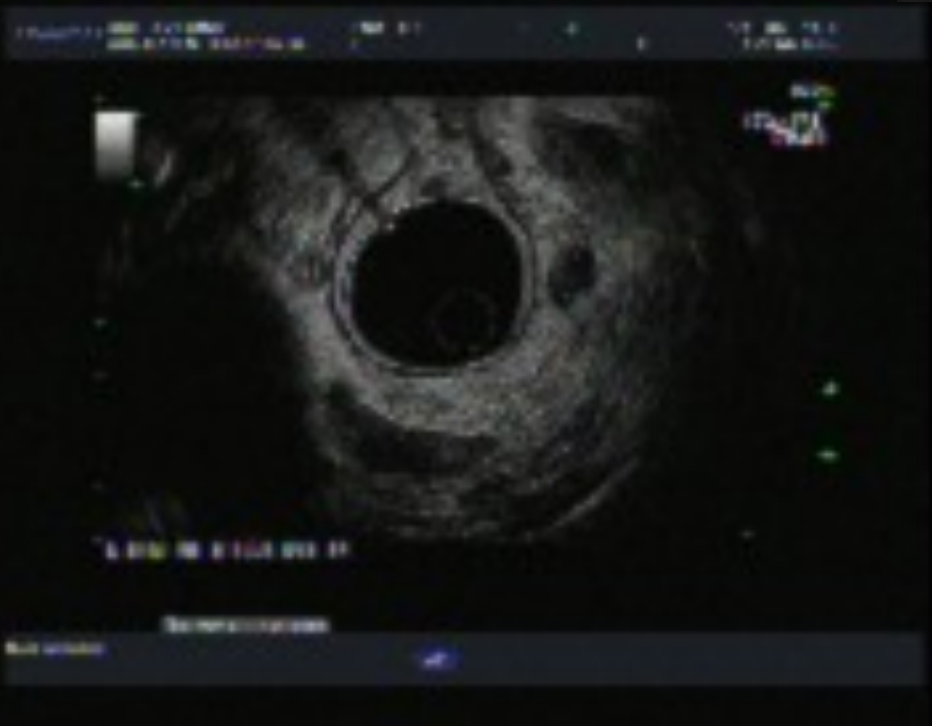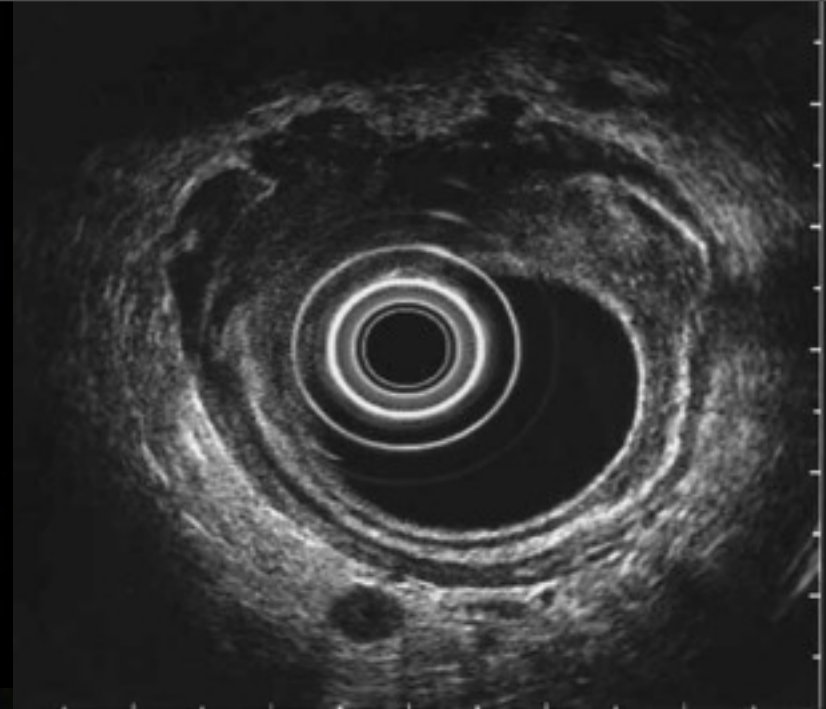
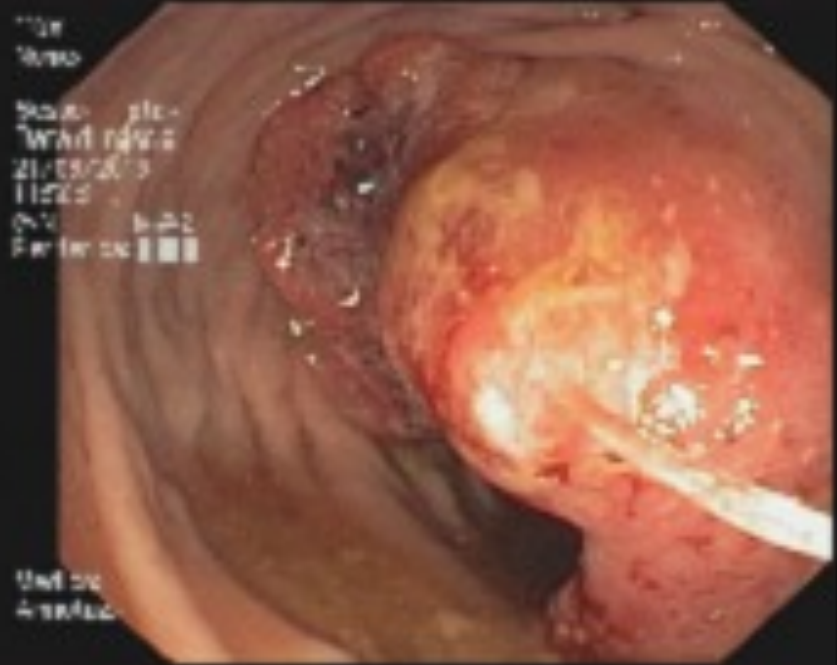- Stadiazione loco-regionale delle neoplasie ano-rettali
- Determinazione del grado di infiltrazione parietale (T del TNM) e la visualizzazione dei linfonodi perirettali ed iliaci (N del TNM)
- Consente anche di eseguire FNA di linfonodi sospetti per metastasi.



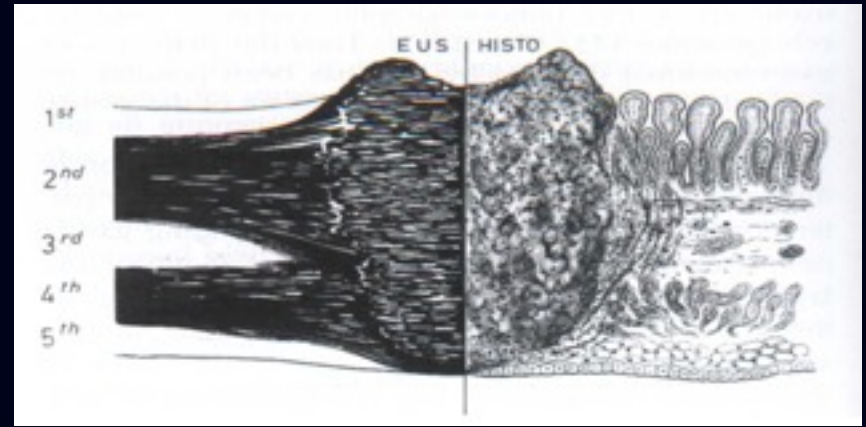
T1N0 ➤ invades submucosa



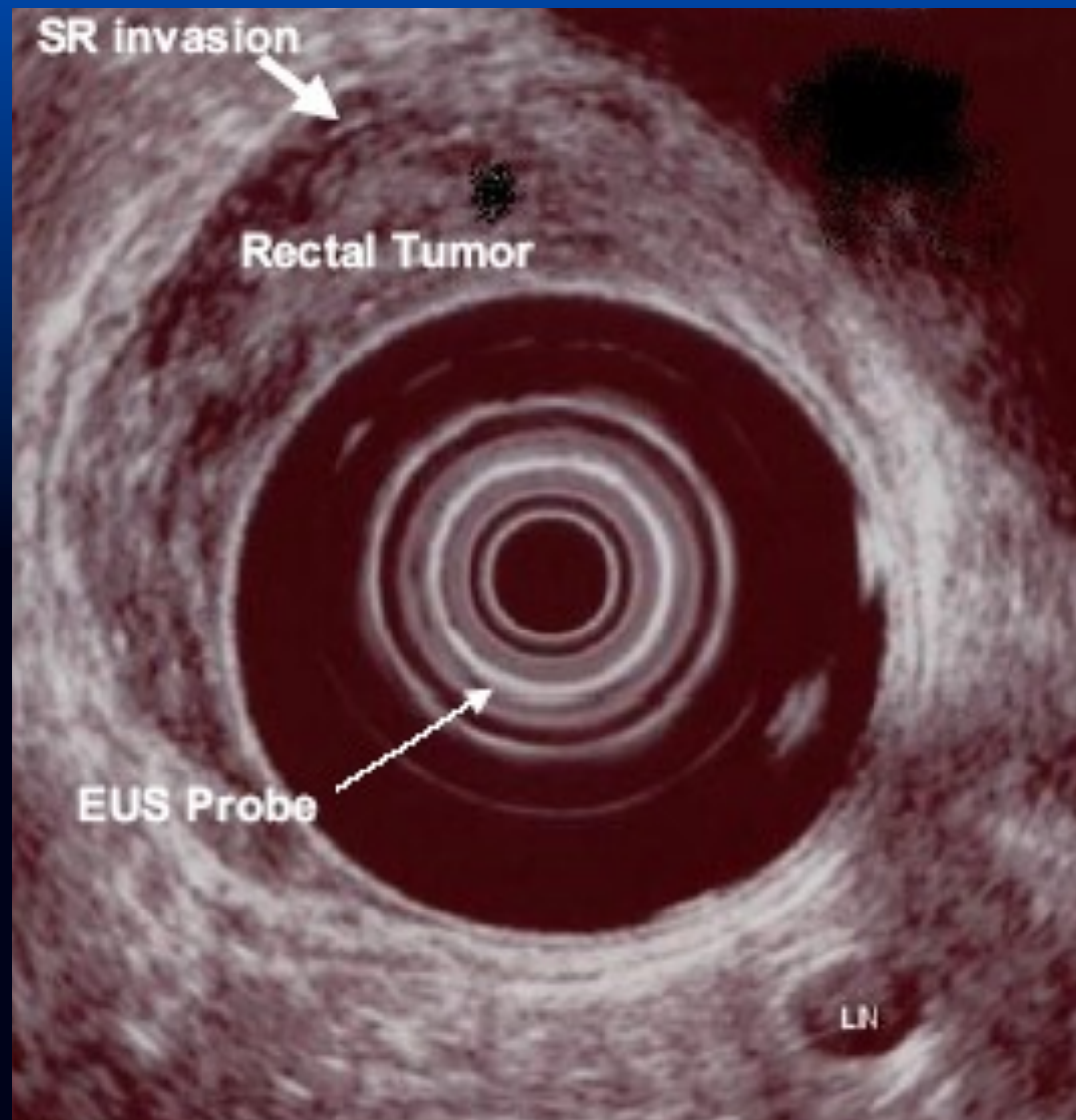
T2N0 ➤ invades muscularis propria



T3N+



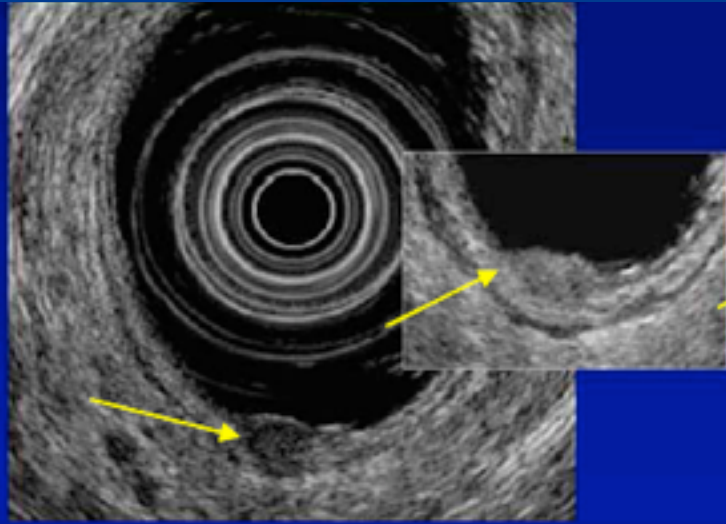
➤ T3N+ through muscularis propria into subserosa



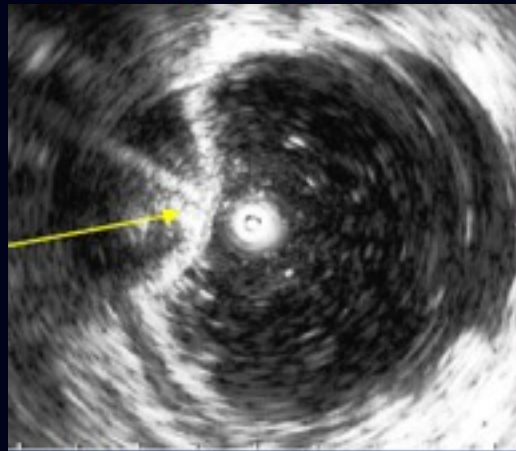
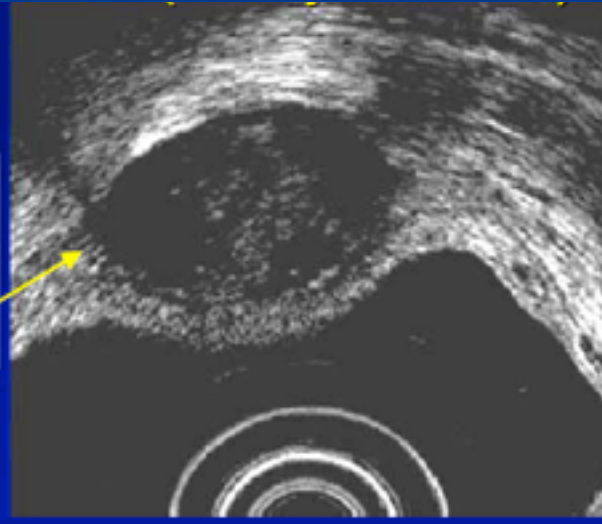
T4N+ rectal cancer with a perirectal lymphnode

Lesion	Endosonographic layer	Endosonographic features
Carcinoid	2nd, 3rd or 4th (often originate in mucosa)	Hypoechoic, sharp margins
GIST	Usually 4th	Hypoechoic, heterogenous, sharp margins
Pneumatosis cystoides intestinalis	2nd and 3rd	Impenetrable to ultrasound. Multiple hyperechoic interfaces just below mucosal layer
Lipoma	3rd	Hyperechoic
Lymphoma	2nd, 3rd or 4th	Hypoechoic inhomogeneous mass
Endometriosis	4th but can involve all layers as endometriosis invades through colonic wall	Usually hypoechoic, may have cystic component
Extrinsic organ	Extracolonic	Appearance of extrinsic organ (vessel, uterus, ovary, etc.)

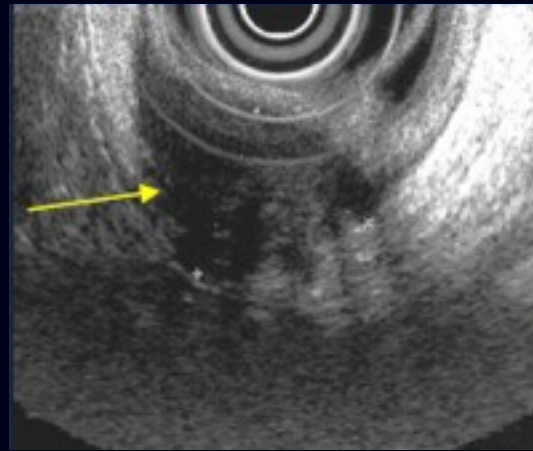
Carcinoid



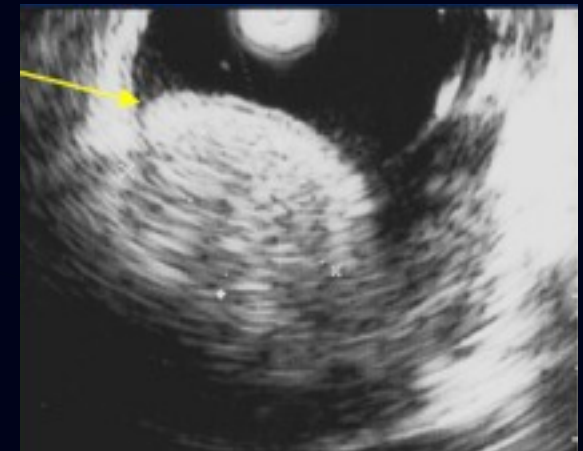GIST



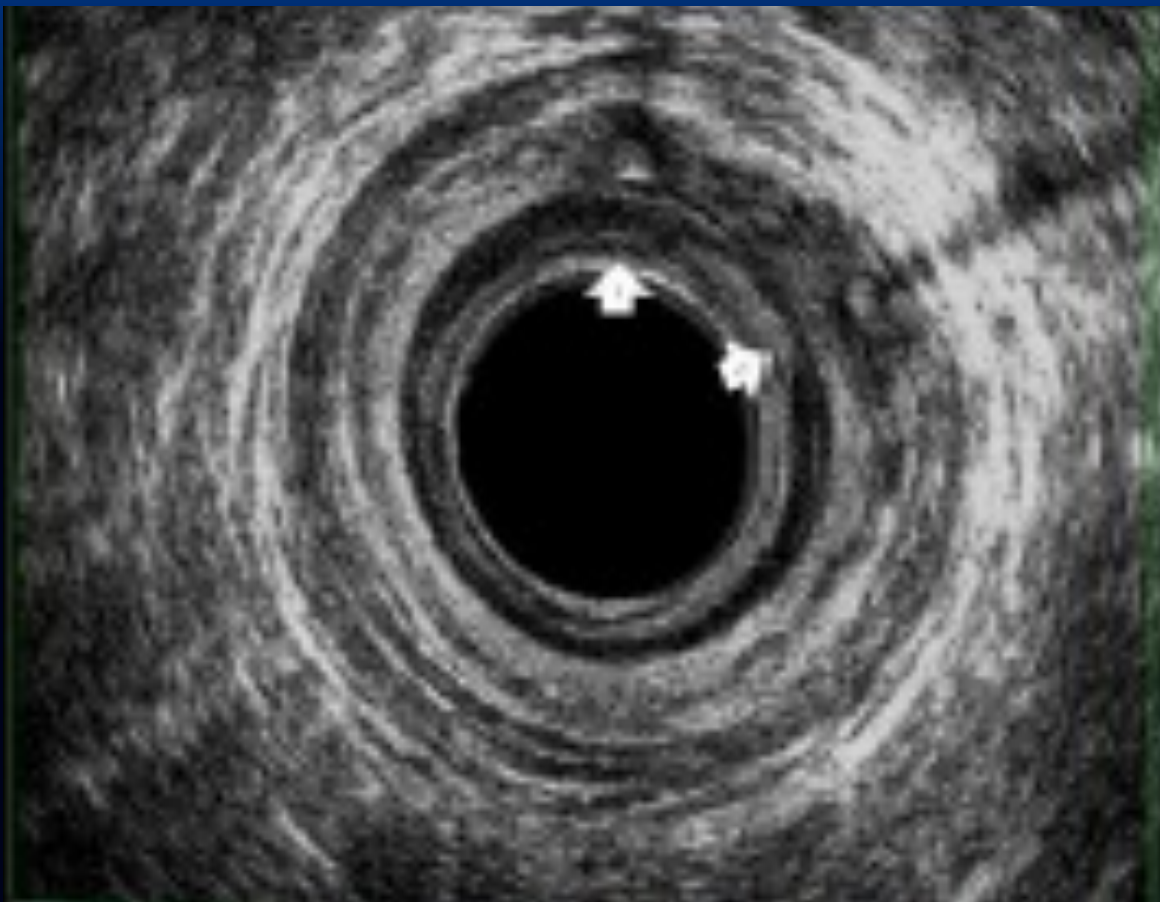
Pneumatosis coli



Endometriosis



Lipoma



Fistola del canale anale