

## The role of endoscopy in the patient with lower GI bleeding

*This is one of a series of statements discussing the use of GI endoscopy in common clinical situations. The Standards of Practice Committee of the American Society for Gastrointestinal Endoscopy (ASGE) prepared this text. In preparing this document, a search of the medical literature pertaining to this topic published between January 1990–March 2013 was performed by using PubMed. Additional references were obtained from the bibliographies of the identified articles and from recommendations of expert consultants. When few or no data exist from well-designed prospective trials, emphasis is given to results from large series and reports from recognized experts. Recommendations for appropriate use of endoscopy are based on a critical review of the available data and expert consensus at the time that the documents are drafted. Further controlled clinical studies may be needed to clarify aspects of this document. This document represents an updated review of previous ASGE guidance on this topic.<sup>1,2</sup> This document may be revised as necessary to account for changes in technology, new data, or other aspects of clinical practice. The recommendations are based on reviewed studies and are graded on the strength of the supporting evidence<sup>3</sup> (Table 1). The strength of individual recommendations is based on both the aggregate evidence quality and an assessment of the anticipated benefits and harms. Weaker recommendations are indicated by phrases such as “We suggest...” whereas stronger recommendations are typically stated as “We recommend...”*

*This document is intended to be an educational device to provide information that may assist endoscopists in providing care to patients. It is not a rule and should not be construed as establishing a legal standard of care or as encouraging, advocating, requiring, or discouraging any particular treatment. Clinical decisions in any particular case involve a complex analysis of the patient's condition and available courses of action. Therefore, clinical considerations may lead an endoscopist to take a course of action that varies from these recommendations.*

### INTRODUCTION

Lower GI bleeding (LGIB) is diagnosed in 20% to 30% of all patients presenting with major GI bleeding.<sup>4-6</sup> The

annual incidence of LGIB is 0.03%, and it increases 200-fold from the second to eighth decades of life.<sup>7-9</sup> The mean age at presentation ranges from 63 to 77 years.<sup>9,10</sup> Approximately 35.7 per 100,000 adults in the United States are hospitalized for LGIB annually, and a full-time gastroenterologist manages more than 10 cases per year.<sup>8,11,12</sup>

Although blood loss from LGIB can range from trivial to massive and life-threatening, the majority of patients have self-limited bleeding and an uncomplicated hospitalization. Compared with acute upper GI bleeding (UGIB), patients with LGIB tend to present with a higher hemoglobin level and are less likely to develop hypotensive shock or require blood transfusions.<sup>6,13</sup> The mortality rate ranges from 2% to 4%<sup>8,10,14</sup> and usually results from comorbidities and nosocomial infections.<sup>15</sup> A recent epidemiologic study reported a decreased incidence of LGIB (41.8/100,000 in 2001 vs 35.7/100,000 in 2009;  $P = .02$ ) and a lower age-adjusted and sex-adjusted case fatality rate (1.93% in 2001 vs 1.47% in 2009;  $P = .003$ ) over the past decade.<sup>12</sup>

### Definitions of LGIB

LGIB historically has been defined as bleeding that emanates from a source distal to the ligament of Treitz.<sup>1,16</sup> After the advent of deep enteroscopy, small-bowel sources have been placed in the category of midgut bleeding, and a new definition of LGIB has been proposed as bleeding from a source distal to the ileocecal valve.<sup>17,18</sup>

Acute LGIB is defined as bleeding of recent duration (<3 days) that may result in hemodynamic instability, anemia, and/or the need for blood transfusion.<sup>13,19,20</sup> Chronic LGIB is the passage of blood per rectum over a period of several days or longer and usually implies intermittent or slow loss of blood. Patients with chronic LGIB present with occult fecal blood, intermittent melena or maroon stools, or scant amounts of bright red blood per rectum.

### ETIOLOGIES OF LGIB

The most common etiologies of LGIB are shown in Table 2.

#### Diverticular bleeding

Colon diverticula are present in up to 30% of patients aged  $\geq 50$  years, with the prevalence increasing to approximately 60% in those aged  $>80$  years.<sup>21-23</sup> Diverticular bleeding accounts for 20% to 65% of acute LGIB episodes.<sup>24-26</sup> Clinically significant bleeding occurs in 3% to 15% of patients with colon diverticula,<sup>27,28</sup> usually as a

**TABLE 1. GRADE system for rating the quality of evidence for guidelines<sup>1</sup>**

Quality of evidence	Definition	Symbol
High quality	Further research is very unlikely to change our confidence in the estimate of effect	⊕⊕⊕⊕
Moderate quality	Further research is likely to have an important impact on our confidence in the estimate of effect and may change the estimate	⊕⊕⊕○
Low quality	Further research is very likely to have an important impact on our confidence in the estimate of effect and is likely to change the estimate	⊕⊕○○
Very low quality	Any estimate of effect is very uncertain	⊕○○○

**TABLE 2. Etiologies of lower GI bleeding**

Diverticular bleeding

Ischemic colitis

Angioectasia

Hemorrhoids

Colorectal neoplasia

Postpolypectomy bleeding

Inflammatory bowel disease

Infectious colitis

NSAID colopathy

Radiation proctopathy

Stercoral ulcer

Rectal varices

Dieulafoy lesion

NSAID, nonsteroidal anti-inflammatory drug.

result of trauma to the vasa recta at the neck or dome of the diverticulum.<sup>11,29</sup> Nonsteroidal anti-inflammatory drugs (NSAIDs) increase the risk for diverticular bleeding,<sup>30,31</sup> while hypertension and anticoagulation also may contribute to severe bleeding.<sup>32-34</sup>

The clinical presentation of diverticular bleeding is characterized by painless hematochezia. Bleeding resolves spontaneously in 75% to 80% of patients but recurs in 25% to 40% within 4 years.<sup>8,27</sup> Early rebleeding is uncommon after endoscopic treatment.<sup>35-39</sup> Older studies of treatments that have used epinephrine and/or thermal coagulation have reported early (<30 days) rebleeding rates ranging from 0% to 38% after endoscopic treatment. Two recent studies reported no early rebleeding after treatment with endoscopic clips and late rebleeding in 18% to 22% of patients.<sup>38,39</sup> Late rebleeding may occur from diverticula at a location different from that of the index bleed.

The diagnosis of diverticular hemorrhage is presumptive in most patients, based on the presence of colon diverticula and the absence of another obvious source of LGIB. A definitive diagnosis is made in approximately 22% of patients who have active bleeding or high-risk stigmata of a visible vessel or clot on colonoscopy.<sup>28,35</sup> Diverticular bleeding is detected by colonoscopy more commonly in the left side of the colon (50%-60%) and by angiography more commonly in the right side of the colon (50%-90%).<sup>8,33,40,41</sup>

### Ischemic colitis

Ischemic colitis is the underlying etiology in 1% to 19% of patients with LGIB and most commonly affects elderly patients.<sup>42-45</sup> Ischemic colitis results from a sudden, often temporary, reduction in mesenteric blood flow secondary to hypoperfusion, vasospasm, or occlusion of the mesenteric vasculature. The typical locations affected by nonocclusive colon ischemia are the “watershed” areas of the colon: the splenic flexure and rectosigmoid junction. A recent review of 313 patients with ischemic colitis reported involvement of the sigmoid colon in 20.8%, descending colon to sigmoid colon in 9.9%, transverse colon to sigmoid colon in 4.2%, and pancolonic involvement in 7.3% of patients.<sup>46</sup> Patients with ischemic colitis often have underlying cardiovascular disease and present with hypotension or hypovolemia, which results in mesenteric hypoperfusion and vasoconstriction. Bleeding results from reperfusion injury after the hypoperfusion has resolved.<sup>47</sup>

Mesenteric occlusion related to cardiac thromboembolism has been reported in up to one-third of patients with ischemic colitis,<sup>48</sup> whereas hypercoagulable states, vasculitis, and medications are less common risk factors.<sup>47,49</sup> The clinical presentation of ischemic colitis is characterized by the sudden onset of cramping abdominal pain, followed by hematochezia or bloody diarrhea within 24 hours.<sup>50</sup> Typical endoscopic findings are submucosal hemorrhage and ulcerations in the colon. These findings are present in a segmental distribution with an abrupt transition between abnormal and normal mucosa. The rectum usually is spared, because of its dual blood supply.<sup>46</sup> A single linear ulcer that runs along the longitudinal axis of the colon on the antimesenteric border (“single-strip” sign)

also may indicate colon ischemia.<sup>51</sup> None of these endoscopic findings are pathognomonic of ischemic colitis, however, and infectious and inflammatory colitides should remain in the differential diagnosis.<sup>11</sup> Angiography should be considered in patients with severe ischemic colitis or right-sided involvement, when there is suspicion for an underlying thromboembolism or concomitant mesenteric ischemia involving the small bowel.<sup>47,52,53</sup>

The majority of patients diagnosed with ischemic colitis improve with conservative management including intravenous hydration and correction of the underlying etiology. Involvement of the right side of the colon and total colon ischemia (usually after a major abdominal surgery) may portend an unfavorable outcome because of concomitant small-bowel ischemia or transmural infarction, and may require surgical management.<sup>54-56</sup>

### Angioectasias

The prevalence of colon angioectasias (also known as angiodysplasias or vascular ectasias) varies with clinical presentation (1%-2% in asymptomatic patients undergoing screening colonoscopy; 40% to 50% in those presenting with hematochezia).<sup>57,58</sup> Studies suggest that angioectasias account for 3% to 15% of patients with LGIB.<sup>13,24,44,45,59</sup> The incidence of angioectasias increases with age, and more than two-thirds of these lesions are seen in patients aged >70 years.<sup>9</sup> Angioectasias are caused by degenerative changes and chronic intermittent low-grade obstruction in the submucosal vessels.<sup>60</sup> They are located predominantly in the cecum and the ascending colon.<sup>61,62</sup> Multiple angioectasias may be seen on colonoscopy and appear as red, flat lesions, ranging in size from 2 mm to several centimeters, with ectatic blood vessels radiating from a central feeding vessel.<sup>9,63</sup>

Risk factors for angioectatic bleeding include advanced age, comorbidities, the presence of multiple angioectasias, and the use of anticoagulants or antiplatelet agents.<sup>60,64</sup> Patients can present with occult bleeding, melena, or painless intermittent hematochezia.<sup>59,65</sup> Colonoscopy has a sensitivity of 80% for detection of angioectasias.<sup>9,63,66</sup> However, the use of narcotics for sedation may reduce mucosal blood flow and impair the detection of these lesions at colonoscopy.<sup>67</sup>

Bleeding from angioectasias in patients with aortic stenosis is termed Heyde syndrome. It is hypothesized that severe aortic stenosis may result in type 2 von Willebrand disease, which precipitates bleeding in patients with underlying angioectasias. There is a high rebleeding rate despite endoscopic treatment, and definitive management of these patients may involve aortic valve replacement.<sup>68</sup>

### Hemorrhoids

Hemorrhoids are a plexus of dilated arteriovenous vessels that arise from the superior and inferior hemorrhoidal veins. These plexuses are located in the submucosa of the

distal rectum and are classified as internal or external, based on their location relative to the dentate line.<sup>11,69</sup> Although hemorrhoids may be present in up to 75% of patients with LGIB, the majority are considered incidental findings.<sup>9</sup> Hemorrhoidal bleeding has been reported to account for only 2% to 10% of acute LGIB.<sup>8,45</sup> However, two recent studies found that hemorrhoids were the underlying etiology in 24% to 64.4% of patients presenting with hematochezia.<sup>25,70</sup> Patients typically present with painless, intermittent, scant hematochezia characterized by bright red blood on the toilet paper, coating the stool, or dripping into the toilet bowl.<sup>11</sup> Anorectal disorders, including hemorrhoids, are discussed in another ASGE guideline.<sup>69</sup>

### Colorectal neoplasia

Clinical features of bowel habit changes and weight loss should raise suspicion for a colorectal neoplasia and prompt colonoscopy in patients with LGIB. Colorectal neoplasia accounts for up to 17% of all etiologies in patients with LGIB and presents more commonly with occult bleeding.<sup>8,10,71,72</sup> Acute LGIB associated with colorectal neoplasia usually results from surface ulcerations of an advanced tumor.<sup>11</sup> Patients with tumors in the right side of the colon are more likely to present with occult blood loss and iron deficiency anemia, whereas those with left-sided tumors more commonly present with hematochezia.<sup>71</sup> Endoscopic treatment for hemostasis is rarely required because bleeding from colorectal neoplasia is slow in the majority of patients.<sup>24</sup>

### Postpolypectomy bleeding

Postpolypectomy bleeding has been reported to account for 2% to 8% of acute LGIB.<sup>9,24</sup> A recent large study of 50,000 colonoscopies that used Medicare claims data reported a bleeding rate of 8.7/1000 procedures.<sup>73</sup> The adverse events of colonoscopy, including postpolypectomy bleeding, are discussed in another ASGE guideline.<sup>74</sup>

### NSAID use

NSAID use is associated with an increased risk of LGIB, including diverticular bleeding.<sup>31,75</sup> A systematic review found that NSAID users had a significantly higher incidence of lower GI adverse events, including bleeding, compared with those who were not NSAID users.<sup>76</sup> The prevalence of NSAID use is reported to be as high as 86% in patients with LGIB.<sup>77</sup> The mechanisms involved in the induction of LGIB by NSAIDs are not well-understood and may include local mucosal trauma and platelet inhibition in susceptible individuals as well as the concomitant use of warfarin and other antiplatelet agents.<sup>78,79</sup>

Use of NSAIDs is associated with exacerbations of inflammatory bowel disease<sup>80,81</sup> and can induce NSAID colopathy, which may be misdiagnosed as inflammatory bowel disease.<sup>82</sup> This disorder is characterized by colon

ulcerations and diaphragm-like strictures, predominantly located in the terminal ileum and right side of the colon. NSAID colopathy may be associated with adverse events of LGIB and perforation.<sup>82</sup>

### Miscellaneous etiologies

Rectal ulcers have been reported in 8% of patients who present with severe hematochezia<sup>83,84</sup> and in 32% of patients who develop LGIB after intensive care unit admissions for other critical illnesses.<sup>85</sup> Patients often have major medical comorbidities of end stage renal disease on hemodialysis, respiratory failure requiring mechanical ventilation, decompensated cirrhosis, or malignancy. Endoscopic findings range from clean-based ulcers (82%) to adherent clots (17%), nonbleeding visible vessels (33%), and active bleeding (50%).<sup>85</sup> Early rebleeding after endoscopic treatment has been reported in 44% to 48% of patients, and a mortality rate of 33% to 48% has been reported in patients with high-risk stigmata who have multiple comorbidities.<sup>83,85</sup>

LGIB has been reported in 4% to 13% of patients with radiation proctopathy. This disorder is caused by radiation-induced endarteritis obliterans, which results in neovascularization and telangiectasias in the rectum.<sup>71</sup>

Patients with inflammatory bowel disease commonly present with LGIB. Acute LGIB requiring hospitalization is uncommon and has been reported to account for only 1.2% to 6% of all admissions in patients with Crohn's disease and 0.1% to 4.2% in patients with ulcerative colitis.<sup>86,87</sup> Clinically significant bleeding in Crohn's disease is more common in patients with colon involvement than in those with isolated small-bowel disease.<sup>88</sup> Bleeding resolves spontaneously in up to 50% of patients, but there is a recurrence rate of up to 35%.<sup>86</sup> Medical management with biologics can be effective in the management of these patients.<sup>89,90</sup>

LGIB occurs in 2.6% of patients with HIV, usually in the setting of AIDS-related thrombocytopenia, and is associated with an inpatient mortality rate of 28%. The most common etiologies of LGIB in these patients are opportunistic infections, including cytomegalovirus, herpes simplex virus, Kaposi's sarcoma, and idiopathic proctocolitis.<sup>91,92</sup>

An upper GI source may be present in 11% to 15% of patients with suspected LGIB, whereas small-bowel sources constitute 2% to 15% of cases.<sup>35,93</sup>

## MANAGEMENT OF LGIB

Algorithms for the management of LGIB are shown in [Figures 1 and 2](#).

### Resuscitation and evaluation

Initial assessment is important in determining whether or not an urgent intervention is necessary in the patient with LGIB. The majority of patients with chronic LGIB,

manifesting as occult fecal blood or scant hematochezia, can be managed electively in the outpatient setting. Patients presenting with acute LGIB with melena or hematochezia usually require inpatient management, because the majority are elderly and have significant comorbidities.<sup>65</sup> These patients should undergo stabilization and resuscitation with crystalloids or blood products.<sup>94</sup> Coagulation factors and platelets may be necessary in patients who are on antithrombotic agents or who have underlying bleeding disorders.<sup>95</sup> Patients with clinical evidence of ongoing or severe bleeding, those with a transfusion requirement of greater than 2 units of packed red blood cells, and those with significant comorbidities may require admission and monitoring in an intensive care unit setting.<sup>9-11,71</sup>

The role of nasogastric tube placement and gastric lavage to exclude an upper GI bleeding source has not been studied prospectively in the setting of suspected acute LGIB. However, this approach should be considered in patients presenting with hematochezia and hemodynamic instability in order to rule out brisk UGIB.<sup>94</sup> An actively bleeding upper GI source is unlikely if bile is seen in the nasogastric lavage, but it cannot be ruled out in the presence of a clear aspirate.<sup>96</sup>

A targeted history including NSAID use, prior bleeding episodes, recent polypectomy, radiation therapy for prostate or pelvic malignancies, inflammatory bowel disease, and risk factors for colorectal cancer may be useful to determine the potential source of bleeding and guide further management.

Predictors of outcome in LGIB are not as well-defined as in UGIB. Several clinical parameters have been identified in an attempt to stratify acute LGIB into high-risk and low-risk patients. By using the predictors of heart rate  $\geq 100$ /minute, systolic blood pressure  $\leq 115$  mm Hg, syncope, nontender abdominal examination, rectal bleeding during the first 4 hours of evaluation, aspirin use, and multiple comorbid illnesses, Strate et al<sup>97</sup> developed and validated a prediction rule to stratify patients into 3 distinct risk categories. Patients with  $\geq 3$  factors are at a high risk of severe bleeding (80%), those with 1 to 3 risk factors are at moderate risk (45%), and those with no risk factors are considered low risk ( $< 10\%$ ).<sup>97,98</sup> Similarly, Velayos et al<sup>99</sup> found that an initial hematocrit  $< 35\%$ , the presence of abnormal vital signs (systolic blood pressure  $< 100$  mm Hg or heart rate  $> 100$ /minute) 1 hour after initial medical evaluation, and gross blood on initial rectal examination were independent predictors of severe LGIB. Kollef et al<sup>100</sup> developed and validated another outcome prediction tool for patients with UGIB and LGIB. The BLEED model uses criteria of ongoing bleeding, low systolic blood pressure, elevated prothrombin time, erratic mental status, and unstable comorbid illness to predict resource utilization and inpatient adverse events, including mortality.<sup>100,101</sup> These models may be useful for guiding decisions regarding inpatient management,

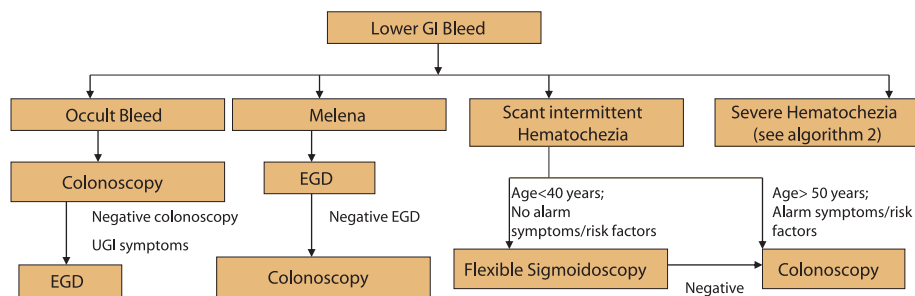


Figure 1. Management of LGIB.

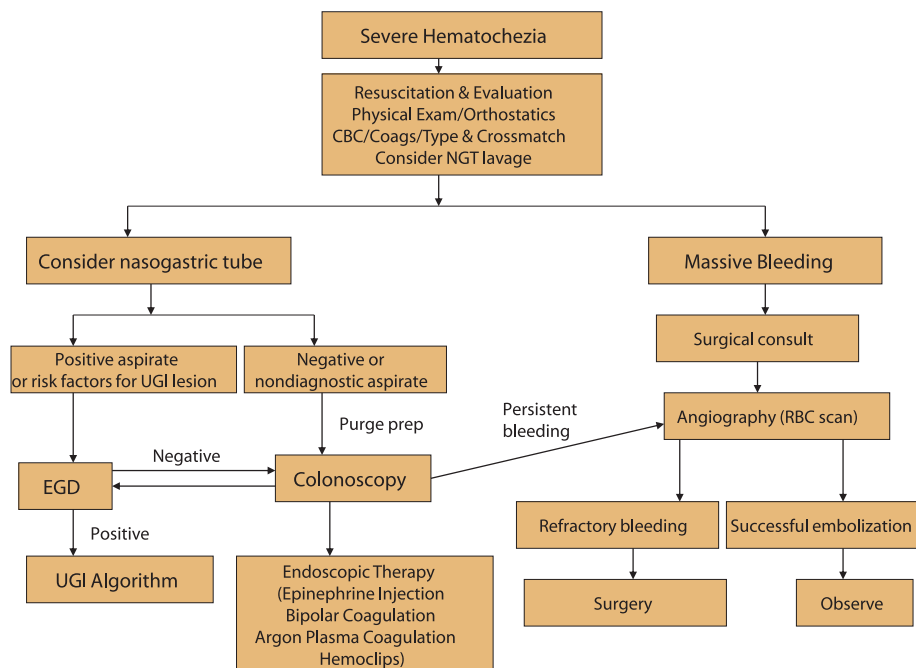


Figure 2. Management of severe hematochezia.

level of care, and necessity for urgent interventions in patients with LGIB, but have not yet been adopted into clinical practice.

### Occult GI bleeding

Patients with occult GI bleeding should undergo colonoscopy for evaluation of underlying colorectal neoplasia.<sup>102</sup> CT colonography may be an alternative in patients who are at high risk for colonoscopy-related adverse events and for the detection of proximal lesions in those who have had an incomplete colonoscopy.<sup>103</sup> An EGD should be considered if a bleeding source is not identified in the colon, especially in those patients with upper GI symptoms, iron deficiency anemia, or NSAID use. The overall yield of EGD has been reported to range from 13% to 41%, with the predominant findings of peptic ulcer

and esophagitis.<sup>104,105</sup> Small-bowel evaluation may be necessary in patients who have fecal occult blood and persistent anemia, after negative EGD and colonoscopy results. The evaluation and management of patients with obscure GI bleeding is discussed in a different ASGE guideline.<sup>106</sup>

### Melena

EGD is the initial test in the evaluation of melena as the majority of these patients have UGIB.<sup>94</sup> Melena also may result from slow bleeding emanating from the colon or small-bowel. A colonoscopy should, therefore, be pursued after negative results on EGD. A recent analysis that used the Clinical Outcomes Research Initiative (CORI) database found an increased likelihood of detecting colorectal cancer in patients with melena compared with average-risk



screening patients (odds ratio 2.87;  $P < .0001$ ).<sup>107</sup> Persistent melena after negative results with bidirectional endoscopy may warrant small-bowel endoscopy for evaluation of OGIB.<sup>106</sup>

### Intermittent scant hematochezia

Chronic intermittent passage of small amounts of blood per rectum is the most common pattern of LGIB<sup>108,109</sup> and usually is caused by an anorectal or distal colon source of bleeding.<sup>110</sup> A digital rectal examination and flexible sigmoidoscopy, with or without anoscopy, may be sufficient for the evaluation of healthy patients aged <40 years.<sup>111</sup> The diagnostic yield of flexible sigmoidoscopy ranges from 9% to 58% in patients with LGIB.<sup>65</sup> A colonoscopy should be pursued in the absence of a definitive source of bleeding on flexible sigmoidoscopy, patients aged >50 years, the presence of iron deficiency anemia, risk factors for colorectal neoplasia, or alarm symptoms of weight loss or bowel habit changes.<sup>102,112</sup>

### Severe hematochezia

An emergent EGD is the test of choice for patients presenting with severe hematochezia and hemodynamic instability for the evaluation and management of high-risk upper GI lesions, followed by a colonoscopy after an upper GI source is ruled out.<sup>94</sup> In hemodynamically stable patients with severe hematochezia, colonoscopy should be performed first, followed by an EGD, if the colonoscopy result is negative.<sup>16</sup> The main advantage of colonoscopy lies in the ability to perform a therapeutic intervention in conjunction with diagnosis of the underlying lesion.<sup>16,24,113</sup> The diagnostic yield of colonoscopy ranges from 45% to 100% in LGIB and is significantly higher than radiologic evaluation with red blood cell scan and angiography.<sup>35,37,114,115</sup>

An urgent colonoscopy is recommended in the evaluation of severe hematochezia and, according to different studies, should be performed within 8 to 24 hours of admission.<sup>35,37,63,115</sup> Early performance of colonoscopy increases both its diagnostic yield and the likelihood of a therapeutic intervention.<sup>35,37,115</sup> Endoscopic therapy is performed in 10% to 40% of patients undergoing early colonoscopy for LGIB, with immediate hemostasis being achieved in 50% to 100% of patients.<sup>24,113</sup> Strate and Syngal<sup>43</sup> showed that endoscopic therapy was successful in 29% of colonoscopies performed within 12 hours, 13% between 12 and 24 hours, 4% between 24 and 48 hours, and 0% performed after 48 hours. Early performance of colonoscopy also reduced the duration of hospitalization and cost of care for patients with LGIB.<sup>43,44,116</sup> However, 2 studies showed no improvement in outcomes of rebleeding or surgery after urgent colonoscopy.<sup>37,93</sup>

Colon preparation is important before colonoscopy to improve visualization, increase the diagnostic yield, and reduce the risk of perforation.<sup>24,35,93,117</sup> Polyethylene glycol-based solutions can be administered orally (or via

nasogastric tube in patients at increased risk of aspiration or who are unable to complete oral consumption) at a rate of approximately 1 L every 30 to 45 minutes until the effluent is free of fecal material.<sup>117</sup> Colonoscopy is performed within 1 to 2 hours of the preparation. The reaccumulation of blood in the colon after preparation may be helpful in localizing the bleeding source.<sup>118</sup>

Several modalities are available for endoscopic treatment of LGIB. These include epinephrine solution injection, thermal contact coagulation, argon plasma coagulation, hemostatic clips, and band ligation. A more in-depth discussion is available in another ASGE guideline.<sup>119</sup>

## ENDOSCOPIC TREATMENT OF ACUTE LGIB

### Endoscopic treatment of bleeding diverticula

Thermal contact modalities, including heater probe and bipolar coagulation, can be used alone or in combination with epinephrine injection for the treatment of bleeding colon diverticula. Epinephrine solution in a dilution of 1:10,000 or 1:20,000 is injected in aliquots of 1 mL to 2 mL at the site of active bleeding or around a nonbleeding visible vessel. An adherent clot, if present, may be guillotined by using a polypectomy snare. The visible vessel can be treated effectively by using a heater probe (10 J-15 J) or bipolar coagulation (10 W-16 W) with 2 to 3-second pulse applications and application of mild contact pressure.<sup>37,36,118,120</sup> Perforation has been reported with contact thermal coagulation in the thin-walled right side of the colon in up to 2.5% of patients,<sup>121</sup> so higher settings or repeated applications should be avoided to prevent transmural injury.

Endoscopic clip placement is an alternative treatment to thermal coagulation and has the advantage of quick and easy application.<sup>122</sup> Clips can be deployed over a bleeding vessel at the neck of the diverticulum or to oppose the walls and close the diverticular orifice, thereby tamponading a vessel within the dome.<sup>39,118</sup> The use of an endocap has been described to evert the diverticulum and facilitate clipping of bleeding vessels within the dome of a diverticulum.<sup>38</sup> There are no reports of early rebleeding after endoscopic treatment with clips.<sup>38,39</sup>

Endoscopic band ligation for treatment of diverticular bleeding has been described in some small series of patients. However, this technique may be limited by inadequate suction of diverticula with small orifices or large domes, and high early rebleeding rates have been observed. Additional studies are necessary to evaluate this technique before it can be adopted into routine clinical practice.<sup>123,124</sup>

A tattoo should be placed adjacent to the bleeding diverticulum, if identified at colonoscopy. This is useful for future identification in anticipation of recurrent bleeding and a necessity for repeat endoscopic or surgical intervention. Placement of an endoscopic clip also may be

useful to allow localization of the bleeding source at angiography.<sup>38,118</sup>

### Endoscopic treatment of bleeding angioectasias

Both contact and noncontact thermal coagulation (argon plasma coagulation) techniques are useful in the endoscopic treatment of angioectasias. Argon plasma coagulation may be the preferred technique because of its ease of application, ability to treat large surface areas, and predictable depth of penetration.<sup>125</sup> Lower power settings of 30 W to 45 W and 1 L/minute argon flow rate are used to decrease the risk for perforation in the thin-walled right side of the colon. The probe preferably should be held from 1 mm to 3 mm away from the mucosal surface and fired at 1 to 2-second pulses.<sup>118</sup> A study that followed 100 patients with angioectasias (31% colon) for a median period of 16 months after argon plasma coagulation showed a significant improvement in hemoglobin levels and reduction in transfusion requirements. There were no adverse events with the procedure.<sup>125</sup> The use of endoscopic clips in conjunction with argon plasma coagulation for treatment of angioectasias also has been reported.<sup>126</sup>

### NONENDOSCOPIC TREATMENT OF ACUTE LGIB

Mesenteric angiography with or without a preceding nuclear red blood cell scan is reserved for patients with severe bleeding who cannot be stabilized or prepped for a colonoscopy and for those who have failed endoscopic management. The multidetector row CT scan may be superior to the nuclear red blood cell scan for evaluation of LGIB. It decreases scan time, allows accurate acquisition of arterial images, and demonstrates contrast material extravasation into any portion of the GI tract.<sup>127</sup> The multidetector row CT scan has therefore replaced the nuclear red blood cell scan at several centers.<sup>128</sup> A mesenteric angiogram can detect bleeding at a rate of 0.5 mL/minute.<sup>118</sup> Superselective embolization with microcoils, polyvinyl alcohol particles, or water-insoluble gelatin (gel foam) has improved the success rate of this technique and decreased the occurrence of the adverse event of bowel infarction. A meta-analysis of angiography and embolization as first-line therapy for LGIB found embolization to be an effective treatment for diverticular bleeding, with successful hemostasis in 85% of patients as compared with 50% of those with bleeding from other sources at 30-day follow-up ( $P < .01$ ).<sup>129</sup> However, in contrast to effective endoscopic treatment, early rebleeding after embolization has been reported in 22% of patients with LGIB.<sup>24</sup> Studies that have compared angiography (with the older technique of vasopressin infusion) to colonoscopy have found a significantly higher diagnostic yield and therapeutic success with endoscopic management.<sup>37,114</sup> Major adverse events, including bowel infarction, nephrotoxicity,

and hematomas may occur in up to 17% of patients who undergo angiography.<sup>24</sup> Angioectasias are more difficult to treat with mesenteric angiography and embolization, as compared to bleeding diverticula with a rebleeding rate of up to 40%.<sup>67</sup>

Surgery is rarely required and should be reserved for the minority of patients who have persistent or refractory diverticular bleeding. Criteria that may be useful in determining the necessity for surgery include hypotension and shock despite resuscitation, persistent bleeding with transfusion of  $\geq 6$  units of packed red blood cells, and lack of a diagnosis despite a pan-intestinal evaluation for persistent bleeding in a surgical candidate.<sup>10,130</sup> It is important to attempt localization of the bleeding site for a segmental colectomy as opposed to proceeding with a subtotal colectomy, which has a significantly higher mortality rate.<sup>130,131</sup> Preferentially, surgery should be performed on an elective basis, because there is a high mortality rate with emergent surgical intervention.<sup>132</sup>

### RECOMMENDATIONS

1. We recommend colonoscopy in patients with occult GI bleeding. (⊕⊕⊕⊕)
2. We recommend EGD in patients with occult GI bleeding if a bleeding source is not identified in the colon, especially in those patients with upper GI symptoms, iron deficiency anemia, or nonsteroidal anti-inflammatory drug use. (⊕⊕⊕○)
3. We suggest small-bowel evaluation after negative EGD and colonoscopy results in patients with occult GI bleeding who have persistent anemia. (⊕⊕○○)
4. We recommend colonoscopy for the evaluation of chronic intermittent scant hematochezia in patients aged  $> 50$  years and for patients who have iron deficiency anemia, risk factors for colorectal neoplasia, or the alarm symptoms of weight loss or bowel habit changes. (⊕⊕⊕○)
5. We suggest that in younger patients presenting with chronic intermittent scant hematochezia without alarm symptoms, a digital rectal examination and flexible sigmoidoscopy may be sufficient evaluation. (⊕⊕○○)
6. We recommend EGD in the initial evaluation of patients with melena followed by colonoscopy if the EGD result is negative. (⊕⊕⊕⊕)
7. We recommend an initial EGD in patients with severe hematochezia and hemodynamic instability to evaluate for a high-risk upper GI lesion, followed by colonoscopy if the EGD result is negative. (⊕⊕⊕⊕)
8. We suggest colonoscopy within 24 hours of admission after a rapid bowel preparation in the evaluation of patients with severe hematochezia. (⊕⊕⊕○)
9. We recommend endoscopic treatment with epinephrine solution injection combined with thermal coagulation or endoscopic clip placement as the preferred

management in patients presenting with diverticular bleeding. (⊕⊕⊕⊕)

10. We recommend endoscopic clip or tattoo placement adjacent to a bleeding diverticulum if identified at colonoscopy for future localization in the event of recurrent bleeding. (⊕⊕⊕⊕)
11. We recommend endoscopic treatment with argon plasma coagulation as the preferred management in patients with bleeding angioectasias. (⊕⊕⊕⊕)
12. We recommend surgical and radiologic consultation in patients presenting with severe hematochezia who cannot be stabilized for endoscopy or in whom endoscopic evaluation has failed to reveal a bleeding source. (⊕⊕⊕⊕)

## DISCLOSURES

*The following authors disclosed a financial relationship relevant to this publication: Dr Saltzman, consultant to Beacon Endoscopy; Dr Khasbab, consultant to Boston Scientific. All other authors disclosed no financial relationships relevant to this article.*

*Abbreviations: LGIB, lower GI bleeding; NSAID, nonsteroidal anti-inflammatory drug; UGIB, upper GI bleeding.*

## REFERENCES

1. American Society for Gastrointestinal Endoscopy. The role of endoscopy in the patient with lower gastrointestinal bleeding. *Gastrointest Endosc* 1998;48:685-8.
2. Davila RE, Rajan E, Adler DG, et al. ASGE Guideline: the role of endoscopy in the patient with lower-GI bleeding. *Gastrointest Endosc* 2005;62:656-60.
3. Guyatt GH, Oxman AD, Vist GE, et al. GRADE: an emerging consensus on rating quality of evidence and strength of recommendations. *BMJ* 2008;336:924-6.
4. Gostout CJ. Acute lower GI bleeding. In: Brandt L, editor. *Current medicine: clinical practice of gastroenterology*. Philadelphia: Churchill Livingstone; 1998. p. 651-2.
5. Gostout CJ, Wang KK, Ahlquist DA, et al. Acute gastrointestinal bleeding. Experience of a specialized management team. *J Clin Gastroenterol* 1992;14:260-7.
6. Peura DA, Lanza FL, Gostout CJ, et al. The American College of Gastroenterology Bleeding Registry: preliminary findings. *Am J Gastroenterol* 1997;92:924-8.
7. Bramley PN, Masson JW, McKnight G, et al. The role of an open-access bleeding unit in the management of colonic haemorrhage: a 2-year prospective study. *Scand J Gastroenterol* 1996;31:764-9.
8. Longstreth GF. Epidemiology and outcome of patients hospitalized with acute lower gastrointestinal hemorrhage: a population-based study. *Am J Gastroenterol* 1997;92:419-24.
9. Bounds BC, Kelsey PB. Lower gastrointestinal bleeding. *Gastrointest Endosc Clin N Am* 2007;17:273-88, vi.
10. Farrell JJ, Friedman LS. Gastrointestinal bleeding in the elderly. *Gastrointest Endosc Clin N Am* 2001;30:377-407, viii.
11. Savides TJ. Lower GI bleeding. In: Ginsberg GG, Kochman ML, Norton ID, et al, editors. *Clinical gastrointestinal endoscopy*, 2nd ed. St. Louis (MO): Elsevier; 2012:164-72.
12. Laine L, Yang H, Chang SC, et al. Trends for incidence of hospitalization and death due to GI complications in the United States from 2001 to 2009. *Am J Gastroenterol* 2012;107:1190-5; quiz 1196.
13. Zuckerman GR, Prakash C. Acute lower intestinal bleeding: part I: clinical presentation and diagnosis. *Gastrointest Endosc* 1998;48:606-17.
14. Richter JM, Christensen MR, Kaplan LM, et al. Effectiveness of current technology in the diagnosis and management of lower gastrointestinal hemorrhage. *Gastrointest Endosc* 1995;41:93-8.
15. Strate LL, Ayanian JZ, Kotler G, et al. Risk factors for mortality in lower intestinal bleeding. *Clin Gastroenterol Hepatol*. 2008;6:1004-10; quiz 955.
16. Eisen GM, Dominitz JA, Faigel DO, et al. An annotated algorithmic approach to acute lower gastrointestinal bleeding. *Gastrointest Endosc* 2001;53:859-63.
17. Raju GS, Gerson L, Das A, et al. American Gastroenterological Association (AGA) Institute technical review on obscure gastrointestinal bleeding. *Gastroenterology* 2007;133:1697-717.
18. Ell C, May A. Mid-gastrointestinal bleeding: capsule endoscopy and push-and-pull enteroscopy give rise to a new medical term. *Endoscopy* 2006;38:73-5.
19. Waye JD. Diagnostic endoscopy in lower intestinal bleeding. In: Sugawa C, Schuman BM, Lucas CE, editors. *Gastrointestinal bleeding*. New York: Igaku Shoin Medical Publishers; 1992. p. 230-41.
20. Zuccaro G. Approach to the patient with acute lower GI bleeding. *ASGE Clinical Update* 1999;7:1-4.
21. Painter NS, Burkitt DP. Diverticular disease of the colon, a 20th century problem. *Clin Gastroenterol* 1975;4:3-21.
22. Parks TG. Natural history of diverticular disease of the colon. *Clin Gastroenterol* 1975;4:53-69.
23. Cheskin LJ, Bohlman M, Schuster MM. Diverticular disease in the elderly. *Gastrointest Endosc Clin N Am* 1990;19:391-403.
24. Strate LL, Naumann CR. The role of colonoscopy and radiological procedures in the management of acute lower intestinal bleeding. *Clin Gastroenterol Hepatol* 2010;8:333-43; quiz e44.
25. Gayer C, Chino A, Lucas C, et al. Acute lower gastrointestinal bleeding in 1,112 patients admitted to an urban emergency medical center. *Surgery* 2009;146:600-6; discussion 606-7.
26. Lee EW, Laberge JM. Differential diagnosis of gastrointestinal bleeding. *Techniques in vascular and interventional radiology* 2004;7:112-22.
27. McGuire HH, Jr. Bleeding colonic diverticula: a reappraisal of natural history and management. *Ann Surg* 1994;220:653-6.
28. McGuire HH, Jr, Haynes BW, Jr. Massive hemorrhage for diverticulosis of the colon: guidelines for therapy based on bleeding patterns observed in fifty cases. *Ann Surg* 1972;175:847-55.
29. Meyers MA, Volberg F, Katzen B, et al. The angioarchitecture of colonic diverticula: significance in bleeding diverticulosis. *Radiology* 1973;108:249-61.
30. Aldoori WH, Giovannucci EL, Rimm EB, et al. Use of acetaminophen and nonsteroidal anti-inflammatory drugs: a prospective study and the risk of symptomatic diverticular disease in men. *Arch Fam Med* 1998;7:255-60.
31. Laine L, Connors LG, Reicin A, et al. Serious lower gastrointestinal clinical events with nonselective NSAID or coxib use. *Gastroenterology* 2003;124:288-92.
32. Lee KK, Shah SM, Moser MA. Risk factors predictive of severe diverticular hemorrhage. *Int J Surg* 2011;9:83-5.
33. Lewis M. Bleeding colonic diverticula. *J Clin Gastroenterol* 2008;42:1156-8.
34. Yamada A, Sugimoto T, Kondo S, et al. Assessment of the risk factors for colonic diverticular hemorrhage. *Dis Colon Rect* 2008;51:116-20.
35. Jensen DM, Machicado GA, Jutabha R, et al. Urgent colonoscopy for the diagnosis and treatment of severe diverticular hemorrhage. *New Engl J Med* 2000;342:78-82.
36. Bloomfield RS, Rockey DC, Shetzline MA. Endoscopic therapy of acute diverticular hemorrhage. *Am J Gastroenterol* 2001;96:2367-72.



37. Green BT, Rockey DC, Portwood G, et al. Urgent colonoscopy for evaluation and management of acute lower gastrointestinal hemorrhage: a randomized controlled trial. *Am J Gastroenterol* 2005;100:2395-402.
38. Kaltenbach T, Watson R, Shah J, et al. Colonoscopy with clipping is useful in the diagnosis and treatment of diverticular bleeding. *Clin Gastroenterol Hepatol* 2012;10:131-7.
39. Yen EF, Ladabaum U, Muthusamy VR, et al. Colonoscopic treatment of acute diverticular hemorrhage using endoclips. *Dig Dis Sci* 2008;53:2480-5.
40. Meyers MA, Alonso DR, Baer JW. Pathogenesis of massively bleeding colonic diverticulosis: new observations. *AJR. Am J Roentgenol* 1976;127:901-8.
41. Bounds BC, Friedman LS. Lower gastrointestinal bleeding. *Gastrointest Endosc Clin N Am* 2003;32:1107-25.
42. Newman JR, Cooper MA. Lower gastrointestinal bleeding and ischemic colitis. *Can J Gastroenterol* 2002;16:597-600.
43. Strate LL, Syngal S. Timing of colonoscopy: impact on length of hospital stay in patients with acute lower intestinal bleeding. *Am J Gastroenterol* 2003;98:317-22.
44. Schmulewitz N, Fisher DA, Rockey DC. Early colonoscopy for acute lower GI bleeding predicts shorter hospital stay: a retrospective study of experience in a single center. *Gastrointest Endosc* 2003;58:841-6.
45. Zuckerman GR, Prakash C. Acute lower intestinal bleeding. Part II: etiology, therapy, and outcomes. *Gastrointest Endosc* 1999;49:228-38.
46. Brandt LJ, Feuerstadt P, Blaszk MC. Anatomic patterns, patient characteristics, and clinical outcomes in ischemic colitis: a study of 313 cases supported by histology. *Am J Gastroenterol* 2010;105:2245-52; quiz 2253.
47. Elder K, Lashner BA, Al Solaiman F. Clinical approach to colonic ischemia. *Cleveland Clin J Med* 2009;76:401-9.
48. Hourmand-Ollivier I, Bouin M, Saloux E, et al. Cardiac sources of embolism should be routinely screened in ischemic colitis. *Am J Gastroenterol* 2003;98:1573-7.
49. Greenwald DA, Brandt LJ, Reinus JF. Ischemic bowel disease in the elderly. *Gastrointest Endosc Clin N Am* 2001;30:445-73.
50. Chait MM. Lower gastrointestinal bleeding in the elderly. *World J Gastrointest Endosc* 2010;2:147-54.
51. Zuckerman GR, Prakash C, Merriman RB, et al. The colon single-stripe sign and its relationship to ischemic colitis. *Am J Gastroenterol* 2003;98:2018-22.
52. Theodoropoulou A, Koutroubakis IE. Ischemic colitis: clinical practice in diagnosis and treatment. *World J Gastroenterol* 2008;14:7302-8.
53. Feuerstadt P, Brandt LJ. Colon ischemia: recent insights and advances. *Curr Gastroenterol Rep* 2010;12:383-90.
54. Scharff JR, Longo WE, Vartanian SM, et al. Ischemic colitis: spectrum of disease and outcome. *Surgery* 2003;134:624-9; discussion 629-30.
55. Flobert C, Cellier C, Berger A, et al. Right colonic involvement is associated with severe forms of ischemic colitis and occurs frequently in patients with chronic renal failure requiring hemodialysis. *Am J Gastroenterol* 2000;95:195-8.
56. Sotiriadis J, Brandt LJ, Behin DS, et al. Ischemic colitis has a worse prognosis when isolated to the right side of the colon. *Am J Gastroenterol* 2007;102:2247-52.
57. Fouch PG, Rex DK, Lieberman DA. Prevalence and natural history of colonic angiodysplasia among healthy asymptomatic people. *Am J Gastroenterol* 1995;90:564-7.
58. Jensen DM, Machicado GA. Diagnosis and treatment of severe hematochezia. The role of urgent colonoscopy after purge. *Gastroenterology* 1988;95:1569-74.
59. Diggs NG, Holub JL, Lieberman DA, et al. Factors that contribute to blood loss in patients with colonic angiodysplasia from a population-based study. *Clin Gastroenterol Hepatol* 2011;9:415-20; quiz e49.
60. Boley SJ, Sammartano R, Adams A, et al. On the nature and etiology of vascular ectasias of the colon: degenerative lesions of aging. *Gastroenterology* 1977;72:650-60.
61. Hochter W, Weingart J, Kuhner W, et al. Angiodysplasia in the colon and rectum: endoscopic morphology, localisation and frequency. *Endoscopy* 1985;17:182-5.
62. Dalle I, Geboes K. Vascular lesions of the gastrointestinal tract [French]. *Acta Gastro-enterologica Belgica* 2002;65:213-9.
63. Green BT, Rockey DC. Lower gastrointestinal bleeding—management. *Gastrointest Endosc Clin N Am* 2005;34:665-78.
64. Sekino Y, Endo H, Yamada E, et al. Clinical associations and risk factors for bleeding from colonic angioectasia: a case-controlled study. *Colorect Dis* 2012;14:e740-6.
65. Strate LL. Lower GI bleeding: epidemiology and diagnosis. *Gastrointest Endosc Clin N Am* 2005;34:643-64.
66. Richter JM, Hedberg SE, Athanasoulis CA, et al. Angiodysplasia: clinical presentation and colonoscopic diagnosis. *Dig Dis Sci* 1984;29:481-5.
67. Brandt LJ, Spinnell MK. Ability of naloxone to enhance the colonoscopic appearance of normal colon vasculature and colon vascular ectasias. *Gastrointest Endosc* 1999;49:79-83.
68. Pate GE, Chandavimol M, Naiman SC, et al. Heyde's syndrome: a review. *J Heart Valve Dis* 2004;13:701-12.
69. Appalaneni V, Fanelli RD, Sharaf RN, et al. The role of endoscopy in patients with anorectal disorders. *Gastrointest Endosc* 2010;72:1117-23.
70. Gralnek IM, Ron-Tal Fisher O, Holub JL, et al. The role of colonoscopy in evaluating hematochezia: a population-based study in a large consortium of endoscopy practices. *Gastrointest Endosc* 2013;77:410-8.
71. Barnert J, Messmann H. Diagnosis and management of lower gastrointestinal bleeding. *Nat Rev Gastroenterol Hepatol* 2009;6:637-46.
72. Schuetz A, Jauch KW. Lower gastrointestinal bleeding: therapeutic strategies, surgical techniques and results. *Langenbecks Arch Surg/Deutsche Gesellschaft für Chirurgie* 2001;386:17-25.
73. Warren JL, Klabunde CN, Mariotto AB, et al. Adverse events after outpatient colonoscopy in the Medicare population. *Ann Int Med* 2009;150:849-57, W152.
74. Fisher DA, Maple JT, Ben-Menachem T, et al. Complications of colonoscopy. *Gastrointest Endosc* 2011;74:745-52.
75. Fouch PG. Diverticular bleeding: Are nonsteroidal anti-inflammatory drugs risk factors for hemorrhage and can colonoscopy predict outcome for patients? *Am J Gastroenterol* 1995;90:1779-84.
76. Laine L, Smith R, Min K, et al. Systematic review: the lower gastrointestinal adverse effects of non-steroidal anti-inflammatory drugs. *Aliment Pharmacol Therapeut* 2006;24:751-67.
77. Lanas A, Sekar MC, Hirschowitz BI. Objective evidence of aspirin use in both ulcer and nonulcer upper and lower gastrointestinal bleeding. *Gastroenterology* 1992;103:862-9.
78. Patrono C. Aspirin as an antiplatelet drug. *New Engl J Med* 1994;330:1287-94.
79. van Dijk KN, Plat AW, van Dijk AA, et al. Potential interaction between acenocoumarol and diclofenac, naproxen and ibuprofen and role of CYP2C9 genotype. *Thrombosis Haemostasis* 2004;91:95-101.
80. Matuk R, Crawford J, Abreu MT, et al. The spectrum of gastrointestinal toxicity and effect on disease activity of selective cyclooxygenase-2 inhibitors in patients with inflammatory bowel disease. *Inflam Bowel Dis* 2004;10:352-6.
81. Biancone L, Tosti C, De Nigris F, et al. Selective cyclooxygenase-2 inhibitors and relapse of inflammatory bowel disease. *Gastroenterology* 2003;125:637-8.
82. Bjarnason I, Hayllar J, MacPherson AJ, et al. Side effects of nonsteroidal anti-inflammatory drugs on the small and large intestine in humans. *Gastroenterology* 1993;104:1832-47.
83. Kanwal F, Dulai G, Jensen DM, et al. Major stigmata of recent hemorrhage on rectal ulcers in patients with severe hematochezia: endoscopic diagnosis, treatment, and outcomes. *Gastrointest Endosc* 2003;57:462-8.
84. Machicado GA, Jensen DM. Endoscopic diagnosis and treatment of severe lower gastrointestinal bleeding. *Indian J Gastroenterol* 2006;25(suppl 1):S43-51.

85. Lin CK, Liang CC, Chang HT, et al. Acute hemorrhagic rectal ulcer: an important cause of lower gastrointestinal bleeding in the critically ill patients. *Dig Dis Sci* 2011;56:3631-7.
86. Robert JR, Sachar DB, Greenstein AJ. Severe gastrointestinal hemorrhage in Crohn's disease. *Ann Surg* 1991;213:207-11.
87. Pardi DS, Loftus EV, Jr, Tremaine WJ, et al. Acute major gastrointestinal hemorrhage in inflammatory bowel disease. *Gastrointest Endosc* 1999;49:153-7.
88. Belaiche J, Louis E, D'Haens G, et al. Acute lower gastrointestinal bleeding in Crohn's disease: characteristics of a unique series of 34 patients. Belgian IBD Research Group. *Am J Gastroenterol* 1999;94:2177-81.
89. Tsujikawa T, Nezu R, Andoh A, et al. Infliximab as a possible treatment for the hemorrhagic type of Crohn's disease. *J Gastroenterol* 2004;39:284-7.
90. Papi C, Gili L, Tarquini M, et al. Infliximab for severe recurrent Crohn's disease presenting with massive gastrointestinal hemorrhage. *J Clin Gastroenterol* 2003;36:238-41.
91. Chalasani N, Wilcox CM. Etiology and outcome of lower gastrointestinal bleeding in patients with AIDS. *Am J Gastroenterol* 1998;93:175-8.
92. Cello JP, Wilcox CM. Evaluation and treatment of gastrointestinal tract hemorrhage in patients with AIDS. *Gastrointest Endosc Clin N Am* 1988;17:639-48.
93. Laine L, Shah A. Randomized trial of urgent vs. elective colonoscopy in patients hospitalized with lower GI bleeding. *Am J Gastroenterol* 2010;105:2636-41; quiz 2642.
94. Hwang JH, Fisher DA, Ben-Menachem T, et al. The role of endoscopy in the management of acute non-variceal upper GI bleeding. *Gastrointest Endosc* 2012;75:1132-8.
95. Anderson MA, Ben-Menachem T, Gan SI, et al. Management of antithrombotic agents for endoscopic procedures. *Gastrointest Endosc* 2009;70:1060-70.
96. Cuellar RE, Gavalier JS, Alexander JA, et al. Gastrointestinal tract hemorrhage: the value of a nasogastric aspirate. *Arch Int Med* 1990;150:1381-4.
97. Strate LL, Orav EJ, Syngal S. Early predictors of severity in acute lower intestinal tract bleeding. *Arch Int Med* 2003;163:838-43.
98. Strate LL, Saltzman JR, Ookubo R, et al. Validation of a clinical prediction rule for severe acute lower intestinal bleeding. *Am J Gastroenterol* 2005;100:1821-7.
99. Velayos FS, Williamson A, Sousa KH, et al. Early predictors of severe lower gastrointestinal bleeding and adverse outcomes: a prospective study. *Clin Gastroenterol Hepatol* 2004;2:485-90.
100. Kollef MH, O'Brien JD, Zuckerman GR, et al. BLEED: a classification tool to predict outcomes in patients with acute upper and lower gastrointestinal hemorrhage. *Critic Care Med* 1997;25:1125-32.
101. Kollef MH, Canfield DA, Zuckerman GR. Triage considerations for patients with acute gastrointestinal hemorrhage admitted to a medical intensive care unit. *Critic Care Med* 1995;23:1048-54.
102. Early DS, Ben-Menachem T, Decker GA, et al. Appropriate use of GI endoscopy. *Gastrointest Endosc* 2012;75:1127-31.
103. Farraye FA, Adler DG, Chand B, et al. Update on CT colonography. *Gastrointest Endosc* 2009;69:393-8.
104. McLoughlin MT, Telford JJ. Positive occult blood and negative colonoscopy—Should we perform gastroscopy? *Can J Gastroenterol* 2007;21:633-6.
105. Allard J, Cosby R, Del Giudice ME, et al. Gastroscopy following a positive fecal occult blood test and negative colonoscopy: systematic review and guideline. *Can J Gastroenterol* 2010;24:113-20.
106. Fisher L, Lee Krinsky M, Anderson MA, et al. The role of endoscopy in the management of obscure GI bleeding. *Gastrointest Endosc* 2010;72:471-9.
107. Etzel JP, Williams JL, Jiang Z, et al. Diagnostic yield of colonoscopy to evaluate melena after a nondiagnostic EGD. *Gastrointest Endosc* 2012;75:819-26.
108. Dent OF, Goulston KJ, Zubrzycki J, et al. Bowel symptoms in an apparently well population. *Dis Colon Rect* 1986;29:243-7.
109. Talley NJ, Jones M. Self-reported rectal bleeding in a United States community: prevalence, risk factors, and health care seeking. *Am J Gastroenterol* 1998;93:2179-83.
110. Nikpour S, Ali Asgari A. Colonoscopic evaluation of minimal rectal bleeding in average-risk patients for colorectal cancer. *World J Gastroenterol* 2008;14:6536-40.
111. Eckardt VF, Schmitt T, Kanzler G, et al. Does scant hematochezia necessitate the performance of total colonoscopy? *Endoscopy* 2002;34:599-603.
112. Peytremann-Bridevaux I, Arditi C, Froehlich F, et al. Appropriateness of colonoscopy in Europe (EPAGE II). Iron-deficiency anemia and hematochezia. *Endoscopy* 2009;41:227-33.
113. Lhewa DY, Strate LL. Pros and cons of colonoscopy in management of acute lower gastrointestinal bleeding. *World J Gastroenterol* 2012;18:1185-90.
114. Strate LL, Syngal S. Predictors of utilization of early colonoscopy vs. radiography for severe lower intestinal bleeding. *Gastrointest Endosc* 2005;61:46-52.
115. Angtuaco TL, Reddy SK, Drapkin S, et al. The utility of urgent colonoscopy in the evaluation of acute lower gastrointestinal tract bleeding: a 2-year experience from a single center. *Am J Gastroenterol* 2001;96:1782-5.
116. Jensen DM, Machicado GA. Colonoscopy for diagnosis and treatment of severe lower gastrointestinal bleeding: routine outcomes and cost analysis. *Gastrointest Endosc Clin N Am* 1997;7:477-98.
117. Elta GH. Urgent colonoscopy for acute lower-GI bleeding. *Gastrointest Endosc* 2004;59:402-8.
118. Wong Kee Song LM, Baron TH. Endoscopic management of acute lower gastrointestinal bleeding. *Am J Gastroenterol* 2008;103:1881-7.
119. Conway JD, Adler DG, Diehl DL, et al. Endoscopic hemostatic devices. *Gastrointest Endosc* 2009;69:987-96.
120. Foutch PG, Zimmerman K. Diverticular bleeding and the pigmented protuberance (sentinel clot): clinical implications, histopathological correlation, and results of endoscopic intervention. *Am J Gastroenterol* 1996;91:2589-93.
121. Barnert J, Messmann H. Lower intestinal bleeding disorders. In: Classen M, Tytgat GN, Lightdale CJ, editors. *Gastroenterological endoscopy*, 2nd ed. New York: Thieme; 2010. p. 641-57.
122. Hokama A, Uehara T, Nakayoshi T, et al. Utility of endoscopic hemoclipping for colonic diverticular bleeding. *Am J Gastroenterol* 1997;92:543-6.
123. Ishii N, Uemura M, Itoh T, et al. Endoscopic band ligation for the treatment of bleeding colonic and ileal diverticula. *Endoscopy* 2010;42(suppl 2):E82-3.
124. Ishii N, Setoyama T, Deshpande GA, et al. Endoscopic band ligation for colonic diverticular hemorrhage. *Gastrointest Endosc* 2012;75:382-7.
125. Kwan V, Bourke MJ, Williams SJ, et al. Argon plasma coagulation in the management of symptomatic gastrointestinal vascular lesions: experience in 100 consecutive patients with long-term follow-up. *Am J Gastroenterol* 2006;101:58-63.
126. Lee TY, Yeh HZ, Yang SS, et al. Successful application of haemoclips plus argon plasma coagulation for angioectasia bleeding with underlying arteriovenous malformation in the colon. *Colorect Dis* 2010;12:e180-1.
127. Jaeckle T, Stuber G, Hoffmann MH, et al. Acute gastrointestinal bleeding: value of MDCT. *Abdom Imaging* 2008;33:285-93.
128. Zink SI, Ohki SK, Stein B, et al. Noninvasive evaluation of active lower gastrointestinal bleeding: comparison between contrast-enhanced MDCT and 99mTc-labeled RBC scintigraphy. *AJR. Am J Roentgenol* 2008;191:1107-14.
129. Khanna A, Ognibene SJ, Koniaris LG. Embolization as first-line therapy for diverticulosis-related massive lower gastrointestinal bleeding: evidence from a meta-analysis. *J Gastrointest Surg* 2005;9:343-52.
130. Bokhari M, Vernava AM, Ure T, et al. Diverticular hemorrhage in the elderly—Is it well tolerated? *Dis Colon Rect* 1996;39:191-5.

- 131. Vernava AM, 3rd, Moore BA, Longo WE, et al. Lower gastrointestinal bleeding. *Dis Colon Rect* 1997;40:846-58.
- 132. Ansari MZ, Collopy BT, Hart WG, et al. In-hospital mortality and associated complications after bowel surgery in Victorian public hospitals. *Aust New Zeal J Surg* 2000;70:6-10.

Prepared by:  
 ASGE STANDARDS OF PRACTICE COMMITTEE  
 Shabana F. Pasha, MD  
 Amandeep Shergill, MD  
 Ruben D. Acosta, MD  
 Vinay Chandrasekhara, MD  
 Krishnavel V. Chathadi, MD

Dayna Early, MD  
 John A. Evans, MD  
 Deborah Fisher, MD  
 Lisa Fonkalsrud, BSN, RN, CGRN, SGNA Representative  
 Joo Ha Hwang, MD  
 Mouen A. Khashab, MD  
 Jenifer R. Lightdale, MD, MPH  
 V. Raman Muthusamy, MD  
 John R. Saltzman, MD  
 Brooks D. Cash, MD, Committee Chair

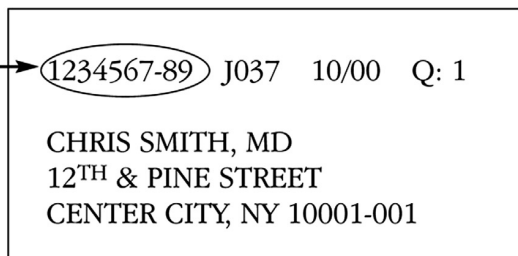
This document is a product of the ASGE Standards of Practice Committee. This document was reviewed and approved by the Governing Board of the American Society for Gastrointestinal Endoscopy.

Access to ***Gastrointestinal Endoscopy Online*** is reserved for all subscribers!

Full-text access to ***Gastrointestinal Endoscopy Online*** is available for all subscribers. ASGE MEMBER SUBSCRIBERS: To activate your individual online subscription, please visit <http://www.asge.org> and follow the instructions. NON-MEMBER SUBSCRIBERS: To activate your individual online subscription, please visit <http://www.giejournal.org> and follow the prompts to activate your *online access*. To activate your account, you will need your subscriber account/membership number, which you can find on your mailing label (*note*: the number of digits in your subscriber account number varies from 6 to 10 digits). See the example below in which the subscriber account number has been circled:

**Sample mailing label**

This is your Nonmember subscriber account number →



Personal subscriptions to ***Gastrointestinal Endoscopy Online*** are for individual use only and may not be transferred. Use of ***Gastrointestinal Endoscopy Online*** is subject to agreement to the terms and conditions as indicated online.