

# A new partially covered nitinol stent for palliative treatment of malignant bile duct obstruction: a multicenter single-arm prospective study

## Authors

G. Costamagna<sup>1</sup>, A. Tringali<sup>1</sup>, D. N. Reddy<sup>2</sup>, J. Devière<sup>3</sup>, M. Bruno<sup>4</sup>, T. Ponchon<sup>5</sup>, H. Neuhaus<sup>6</sup>, M. Mutignani<sup>1</sup>, G. V. Rao<sup>2</sup>, S. Lakhtakia<sup>2</sup>, O. Le Moine<sup>3</sup>, P. Fockens<sup>4</sup>, E. A. J. Rauws<sup>4</sup>, V. Lepilliez<sup>5</sup>, B. Schumacher<sup>6</sup>, A. Seelhoff<sup>6</sup>, D. Carr-Locke<sup>7</sup>

## Institutions

Institutions are listed at the end of article.

**submitted** 18 April 2010  
**accepted after revision**  
 11 October 2010

## Bibliography

**DOI** <http://dx.doi.org/10.1055/s-0030-1256294>  
 Published online  
 28 February 2011  
 Endoscopy 2011; 43:  
 317–324 © Georg Thieme  
 Verlag KG Stuttgart · New York  
 ISSN 0013-726X

## Corresponding author

**G. Costamagna, MD**  
 Digestive Endoscopy Unit,  
 Catholic University  
 Largo A. Gemelli 8  
 00168 Rome  
 Italy  
 Fax: +39-06-30156581  
[gcostamagna@rm.unicatt.it](mailto:gcostamagna@rm.unicatt.it)

**Background and study aims:** Covered self-expanding metal stents (SEMSs) have proven effective for managing malignant bile duct strictures and may reduce risk of tumor ingrowth. A new nitinol partially covered biliary SEMS was prospectively evaluated.

**Patients and methods:** 70 patients with inoperable extrahepatic biliary obstructions were enrolled in a prospective multicenter trial, and followed up to 6 months or death, whichever came first. Primary endpoint was adequate palliation defined as absence of recurrent biliary obstruction from partly covered SEMS placement to end of follow-up.

**Results:** Mean age of the patients was 69 years and 52% were men. Pancreatic carcinoma was present in 68%. One stent was placed in 67 patients, two patients received two, and in one patient a guide wire could not traverse the stricture.

In 55% of patients the SEMS was inserted de novo and in 45% for exchange with a plastic stent. Technical success was 97%. At 6 months, 62% of patients were free of obstructive symptoms; compared with baseline the mean number of symptoms per patient was significantly reduced (3.1 at baseline, 0.6 at 6 months;  $P < 0.0001$ ) and total bilirubin levels dropped by 73%. There were four cases of recurrent biliary obstruction, due to stent migration (2), tumor overgrowth (1), and sludge formation (1). Device-related complications included cholecystitis (3), right upper quadrant pain (1), and moderate pancreatitis (1). No tumor ingrowth was reported.

**Conclusions:** This new partially covered nitinol SEMS is easily inserted, and safe and effective in the palliation of biliary obstruction secondary to malignant bile duct strictures.

## Introduction

Endoscopic stent insertion is the gold standard for palliation of malignant nonhilar biliary strictures. Since their introduction in the early 1990s, uncovered self-expanding metal stents (SEMSs) have been shown to provide longer patency than plastic stents [1,2] and their use may reduce or even avoid the need for periodic stent exchange [3,4]. It is now generally accepted that SEMS placement is the appropriate palliative procedure for patients without distant metastases and with a life expectancy of at least 4 to 6 months [5–9]. Two main problems that can affect the patency and performance of an uncovered biliary SEMS are tissue ingrowth and high linear tension. Tissue ingrowth from hyperplasia or neoplastic growth through the mesh of the stent is one of the main causes of occlusion of the uncovered SEMS [10,11]. Therefore SEMSs with a plastic polymer covering were developed [12–15]. High linear tension, namely the tendency of some

stents to straighten, especially with the stainless-steel or Elgiloy SEMS, can lead to impaction of the proximal end of the SEMS against the duct wall in cases of angulated bile ducts, leading to stent malfunction [16]. This problem can potentially be solved by the use of more flexible metals such as nitinol.

The aim of the present study was to evaluate a new nitinol partially covered biliary SEMS for the palliative treatment of malignant non hilar bile duct obstruction.

## Materials and methods

### Device and procedure

The WallFlex Biliary RX Partially Covered Stent (PC biliary WallFlex; Boston Scientific, Natick, Massachusetts, USA) (● Fig. 1) has a platinum core with nitinol encasement (Platinol) designed to enhance flexibility and radiopacity while maintaining adequate radial force. The covering



**Fig. 1** The partially covered biliary WallFlex self-expanding metal stent with distal retrieval loop (arrow).

is made of Permalume, a translucent silicone polymer, on the inside of the stent mesh. The uncovered proximal and distal ends of the stent are flared. The stent has a distal retrieval loop for acute removability and repositioning. The delivery system is inserted over a 0.035-inch guide wire using the “rapid exchange” system [17]. The delivery system has an 8.5-Fr diameter. Stent sizes are 60 mm length × 10 mm diameter, 40 mm length × 10 mm diameter, 80 mm length × 10 mm diameter, or 60 mm length × 8 mm diameter.

Stent placement was performed in accordance with the manufacturer's directions. Features of the common bile duct stricture, such as angulation and length, were evaluated at cholangiography. The stricture was passed with a guide wire which, when possible, was stabilized by placing the tip of the guide wire in a peripheral intrahepatic duct. The stent was advanced over the guide wire. The 8.5-Fr delivery system of the PC biliary WallFlex usually crossed the stricture without the need for pre-stenting dilation. The stent was released under fluoroscopic and endoscopic control. The length of the stent was chosen so that the proximal end was 1–2 cm beyond the stricture, assuring however that the proximal end of the stent was below the hilum. The distal uncovered portion was left outside the papilla. During deployment, the distal end of the stent was identified endoscopically through the yellow marker on the inner catheter of the delivery system. Correct positioning and performance of the stent was assessed immediately after deployment by contrast injection through a standard catheter and by the appearance of pneumobilia. Post-stenting dilation was not routinely performed since nitinol stents tend to expand fully after 48–72 h. **Fig. 2** illustrates the procedure.

### Study design

This multicenter, single-arm, prospective study enrolled patients at six centers located in Belgium, France, Germany, India, Italy, and The Netherlands. The study protocol and informed consent forms were approved by the ethics committee at each participating center. All patients provided informed consent prior to initiation of stent placement.

Inclusion criteria were: (i) age ≥ 18 years; (ii) jaundice due to inoperable extrahepatic malignant biliary obstruction; and (iii) ability to provide written informed consent and comply with the study procedures. Exclusion criteria were: (i) participation in

an investigational study within 90 days prior to the date of patient consent; (ii) presence of a metal biliary, esophageal, or duodenal stent; (iii) contraindication to endoscopic procedures; or (iv) known sensitivity to any components of the stent or delivery system.

The effectiveness of the device was measured in terms of adequacy of palliation of the biliary stricture, defined as absence of recurrent biliary obstruction within 6 months or prior to death, whichever came first. Recurrent biliary obstruction was determined by the treating physician based on symptoms (i.e. jaundice or cholangitis) and/or abnormal or worsening liver function tests (LFTs).

The safety of the device was evaluated by the occurrence and severity of device-related and procedure-related adverse events. Each adverse event, defined as any untoward medical occurrence in a study subject, was classified by the treating investigator as “serious” or “non-serious,” “unanticipated” or “anticipated,” and its severity described as “mild,” “moderate,” or “severe.” Relatedness to device and procedure was also recorded, as “unrelated,” “unlikely,” “possibly,” “probably,” or “definitely.” An unanticipated adverse device effect (UADE) was defined as any device-related serious adverse event that was not identified in the risk analysis of the study protocol.

Technical success was determined on the basis of the ability to deploy the stent in a satisfactory position across the stricture. The need for re-intervention, defined as any procedure to improve biliary drainage after insertion of the initial study stent, was also evaluated.

Symptoms of biliary obstruction (jaundice, itching, right upper quadrant abdominal pain, nausea, vomiting, fever, and dark urine) at each follow-up were recorded, as well as the time to recurrent biliary obstruction (relapsing jaundice or cholangitis). Total bilirubin was measured at baseline and at month 1.

The ability to remove/reposition the stent at initial placement without any clinically significant complications or technical difficulties was also assessed.

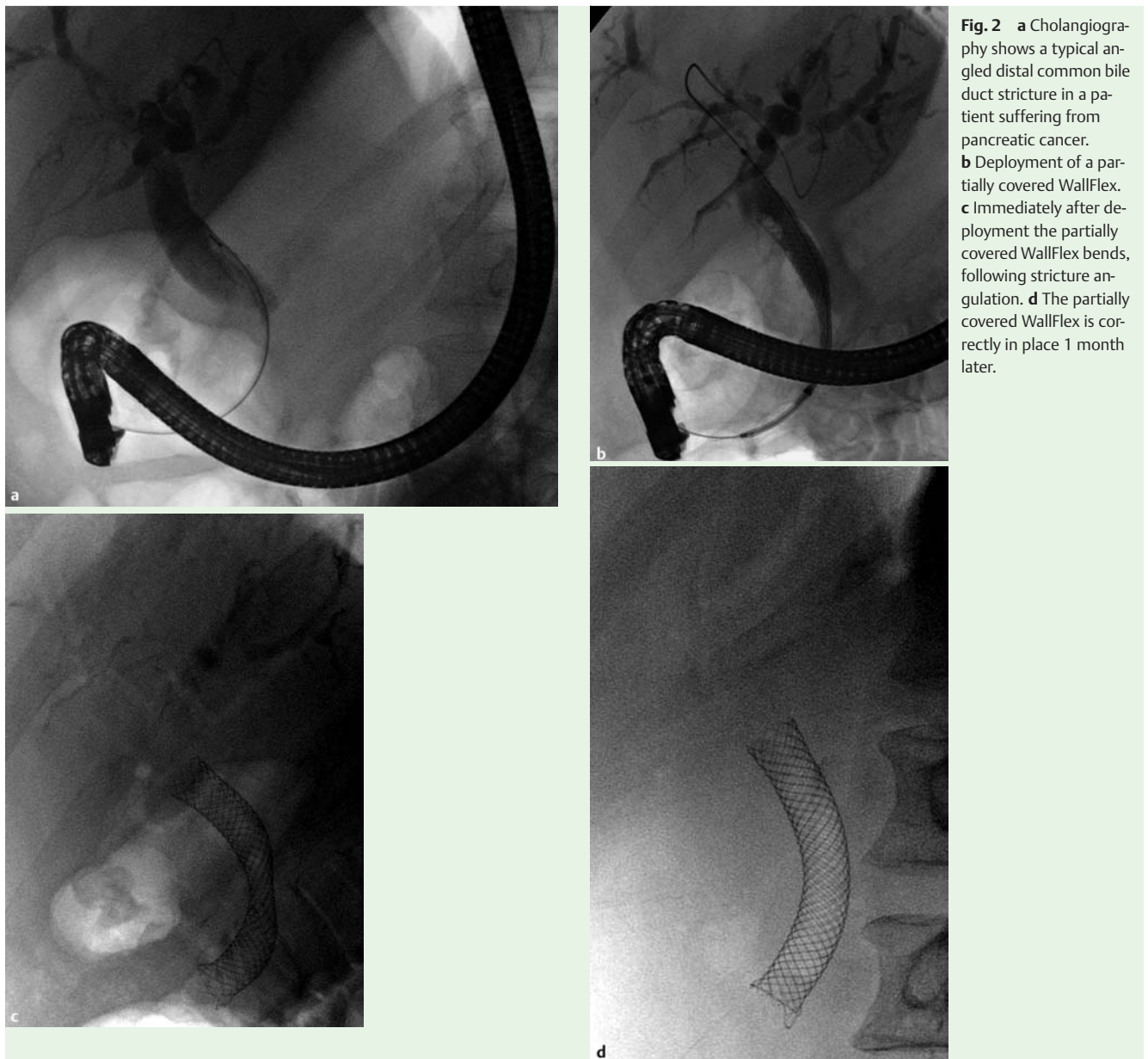
Patients were followed up till death or 6 months, whichever came first, and visits were conducted in person or via phone at weeks 1 and 2, and months 1, 3, and 6 after stent placement. Symptoms of stent malfunction, mainly recurrent cholangitis, and other adverse events were assessed at each visit. If obstructive symptoms returned during the study, an unscheduled visit, including imaging and LFTs as needed, was arranged in order to evaluate possible stent malfunction.

Endpoint assessments of recurrent biliary obstruction, stent occlusion, and stent migration, and of any adverse events resulting in death were adjudicated by an independent medical reviewer (D. C.-L.), an expert in biliary stenting, who had no affiliations with the sponsor or any study centers.

### Statistical analysis

The findings of this prospective study were used for submission to the Food and Drug Administration (FDA) in the USA, which resulted in product clearance for commercialization. The FDA required that effectiveness assessments be made on “evaluable” patients, which the FDA defined as patients who received the investigational stent and had at least 1 week of follow-up.

The study's sample size calculation was based on assessment of the recurrent biliary obstruction rate at 6 months or death (Recurrence rate). An exact binomial test was used to test the null hypothesis  $H_0$ : Recurrence rate ≥ 25% against the alternative hypothesis  $H_a$ : Recurrence rate < 25%. This resulted in a sample size



of 55 evaluable patients, using a significance level of 5%, a power of 90%, and an expected rate of 10% under  $H_0$ . Allowing for about 20% attrition, up to 70 patients were enrolled.

A paired  $t$  test was used to test the significance of the reduction in the mean number of symptoms from baseline to 6 months, using the subset of patients with paired data available.

Kaplan-Meier analysis was used to determine the rate of recurrence of obstruction based on available follow-up information and with information censored beyond 6 months after stent placement.

## Results



### Patient characteristics

Between July and November 2007 a total of 70 patients were enrolled, of whom 69 received a stent. (The single failure was due to inability to pass a guide wire through the stricture.) Baseline characteristics are presented in [Table 1](#). Two patients were lost to follow-up and one patient withdrew consent before the

week 1 follow-up visit, leaving 66 evaluable patients. A total of 71 partially covered nitinol biliary SEMSs were deployed, with two patients requiring two stents, necessitated by the length of their strictures. The stent size most commonly used in this study was 60 mm length  $\times$  10 mm diameter, in 76% (54/71) of stent placements.

The malignant common bile duct stricture was due to pancreatic cancer in the majority of patients (68.1%) and was most commonly located in the distal common bile duct (66.7%).

At the time of insertion of the novel stent, previously inserted plastic stents were removed in 31/69 of the patients (44.9%) and in 34/69 of patients (49.3%) sphincterotomy had previously been performed.

The most commonly reported symptoms at baseline included jaundice (86.4%), dark urine (60.6%), right upper quadrant pain (51.5%), and itching (51.5%) ([Table 2](#)).

The mean duration in the study for all treated patients was 134.5 days (range 5–225, median 144). The course of patients through the study is shown in [Fig. 3](#).

**Table 1** Patient, disease, and stent characteristics.

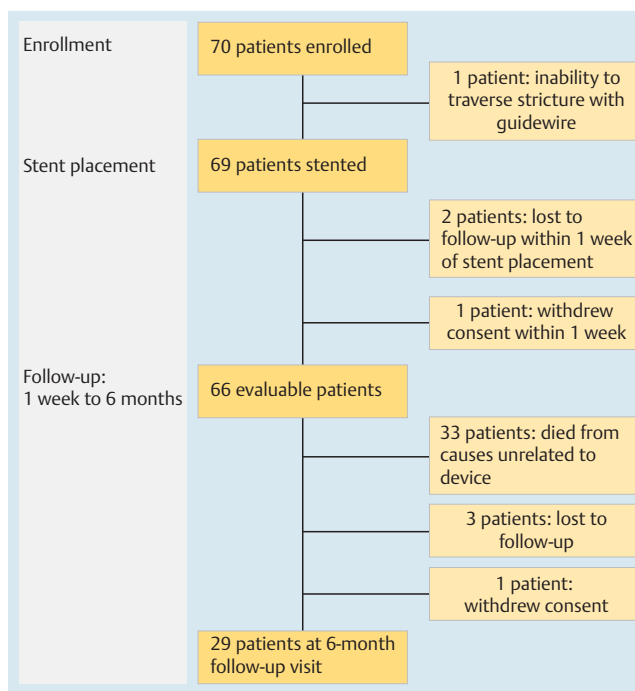
Characteristics	Patients*
Male, n (%)	36 (52.2)
Age, mean (range), years	68.6 (34–92)
<b>Malignant cause of bile duct stricture, n (%)</b>	
Pancreatic	47 (68.1)
Cholangiocarcinoma	9 (13.0)
Ampullary	4 (5.8)
Gallbladder	3 (4.3)
Metastases from colon	2 (2.9)
Primary liver cancer invading common bile duct	1 (1.4)
Metastases from esophageal	1 (1.4)
Metastases from lung	1 (1.4)
Metastases from breast	1 (1.4)
<b>Stricture location, n (%)</b>	
Distal common bile duct	46 (66.7)
Mid common bile duct	15 (21.7)
Papilla	6 (8.7)
Proximal common bile duct	2 (2.9)
<b>Size of study stent†, length in mm × diameter in mm, n (%)</b>	
60 × 10	54 (76.1)
40 × 10	13 (18.3)
80 × 10	3 (4.2)
60 × 8	1 (1.4)

\* Patient characteristics are reported for all patients with a stent (n = 69).

† 71 stents were placed.

### Adequacy of palliation

At the end of follow-up, adequate clinical palliation of biliary obstruction was achieved in 62/66 of patients (94%). Treatment was not effective in four patients (6%) with recurrent biliary obstruction due to stent occlusion (2) or stent migration (2). This low rate of recurrent biliary obstruction led to the rejection of the null hypothesis  $H_0$ : Recurrence rate  $\geq 25\%$  in favor of the alternative hypothesis  $H_a$ : Recurrence rate  $< 25\%$  ( $P < 0.0001$ ).

**Fig. 3** Course of patients during the study.

### Safety

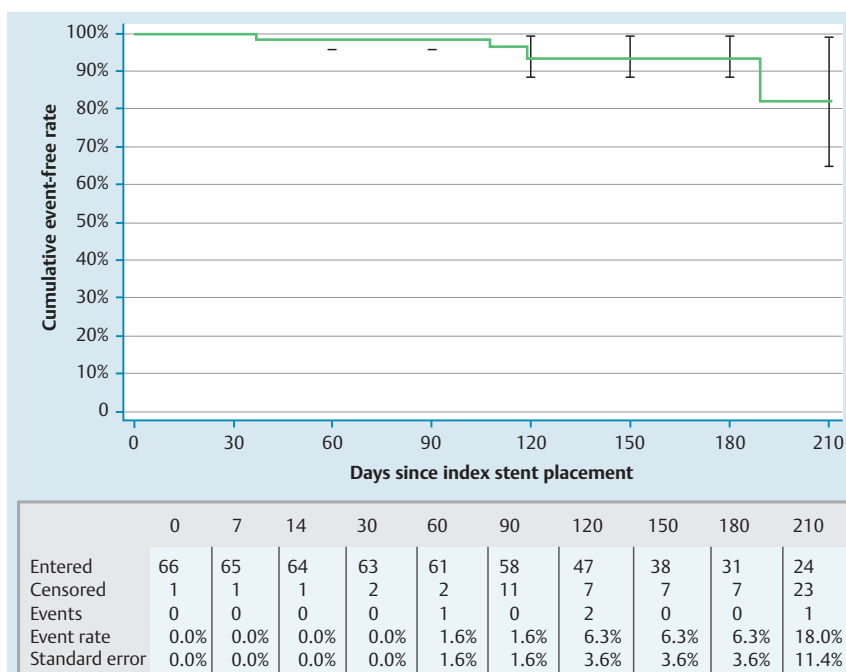
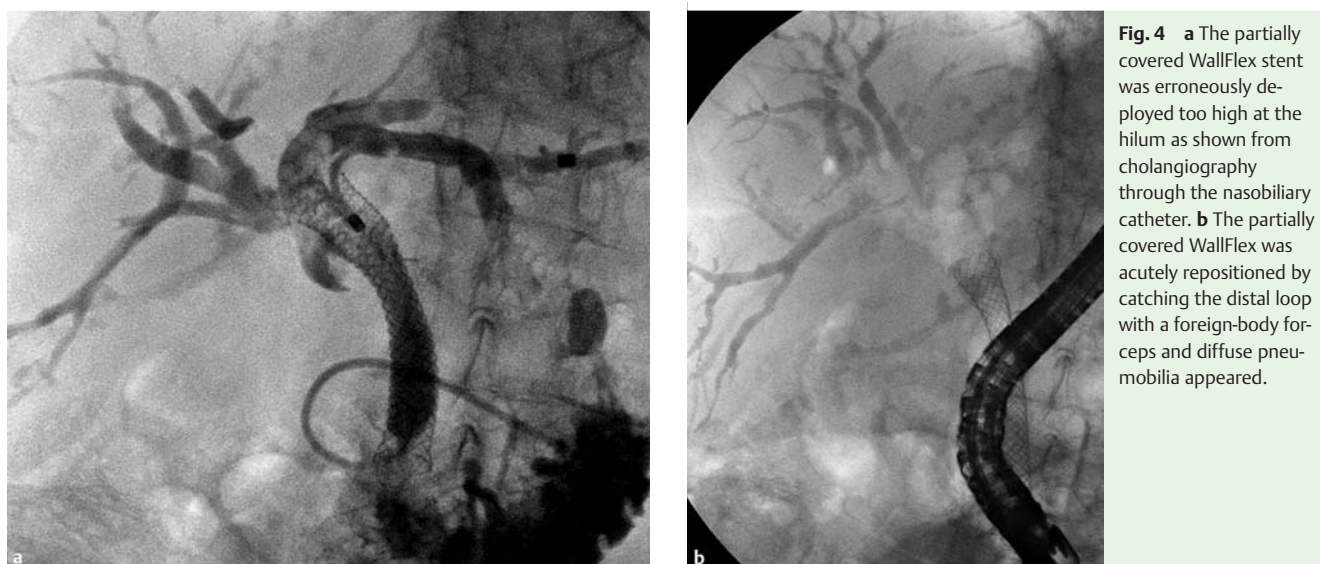A total of 107 adverse events were reported, of which 55 were considered to be serious. There were no unanticipated adverse events. The highest percentage of serious adverse events was related to pancreatic carcinoma (32%), which resulted in death for the majority of patients. Nine of the reported adverse events were device-related and comprised recurrence of biliary obstruction (4), cholecystitis (3), pancreatitis (1) and right upper quadrant pain (1). Details are provided below.

**Table 2** Biliary obstruction symptoms recorded during follow-up in evaluable patients after placement of a partially covered biliary WallFlex self-expanding metal stent.

	Baseline	Week 1	Week 2	Month 1	Month 3	Month 6
Evaluative patients n	66	57	59	62	46	29
Symptom*						
Jaundice						
n	57	21	13	4	3	2
%	86.4	36.8	22.0	6.5	6.5	6.9
Itching						
n	34	6	4	3	2	0
%	51.5	10.5	6.8	4.8	4.3	0.0
Right upper quadrant abdominal pain						
n	34	17	17	11	6	4
%	51.5	29.8	28.8	17.7	13.0	13.8
Nausea						
n	14	4	6	7	7	3
%	21.2	7.0	10.2	11.3	15.2	10.3
Vomiting						
n	6	0	5	3	2	2
%	9.1	0.0	8.5	4.8	4.3	6.9
Fever						
n	14	1	5	1	2	2
%	21.2	1.8	8.5	1.6	4.3	6.9
Dark urine						
n	40	9	4	2	3	1
%	60.6	15.8	6.8	3.2	6.5	3.4

\* Some patients had more than one symptom.





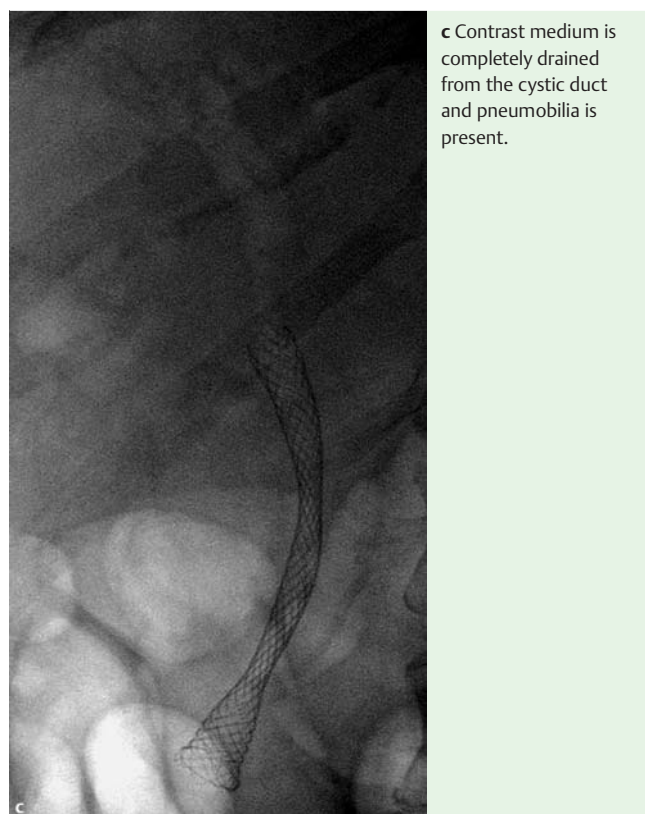
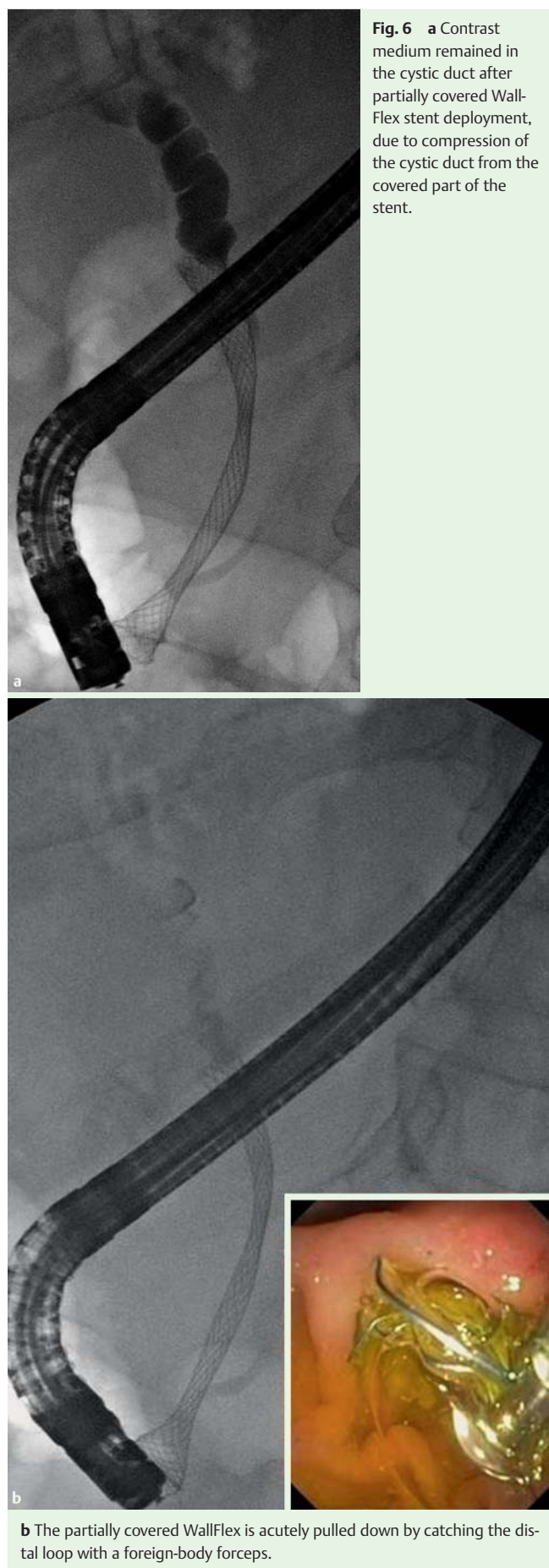
**Fig. 5** Kaplan-Meier analysis of estimated re-obstruction rate in 66 evaluable patients, after insertion of a partially covered nitinol self-expanding metal stent (SEMS).

The four reports of recurrent biliary obstruction comprised: two due to stent migration (day 111 and day 189), both treated by endoscopic removal of the migrated study stent and placement of another non-study SEMS; one due to tumor overgrowth (day 35) treated endoscopically by placement of a non-study stent inside the study stent; and one due to sludge proximal to the stent (day 103), treated endoscopically by removal of the sludge without dislocation of the stent. Regarding the three cases of cholecystitis (days 4, 20, and 71), in two patients this was of moderate severity and resolved with antibiotics and cholecystostomy; in one patient with portal vein thrombosis, who was undergoing palliative chemotherapy with gemcitabine, it was severe and resolved with cholecystectomy. One reported occurrence of moderate pancreatitis was resolved after conservative treatment, and one reported occurrence of mild right upper quadrant pain was treated conservatively.

In addition to the nine complications reported above, there was one intervention related to a nasobiliary drain. This had been left in place in one patient after successful study stent placement to drain sludge associated with previous plastic stenting. Proximal migration of the study stent was incidentally noted after 2 days despite absence of symptoms of biliary obstruction. The distal end of the stent was successfully repositioned into the duodenum to avoid hilar occlusion (● Fig. 4).

### Technical success

Technical success in correct stent deployment was achieved in 68/69 patients (98.6%). Incorrect stent placement position led to one technical failure in a case where the stent engaged the edge of the reconstraint band of the delivery system as it was withdrawn. This patient was reported to have a low confluence of the bile duct and the upper end of the stent extended into the left hepatic duct. At 2 days post-placement, the stent was repositioned.



tioned distally by 1–2-cm using rat-tooth forceps, after which the stent remained in place with good clinical function until the patient's death due to underlying disease at 112 days post-placement.

In three patients, stent expansion immediately post-placement was considered inadequate, but the stent was not removed and all three patients completed the study without re-intervention. In one patient, an 8-cm partially covered biliary WallFlex stent was placed, but appeared to be too long as it extended 3 cm out of the papilla. Stent removal was not attempted, but 2 cm of the duodenal end of the stent was cut off using argon plasma coagulation.

### Biliary obstruction symptoms

Patients experienced a statistically significant reduction in their biliary obstruction symptoms as demonstrated by the decrease in number of symptoms at each visit compared with baseline (Table 2). The mean number of all reported biliary obstruction symptoms was 0.6 at month 6 compared with 3.1 at baseline. When the subset of 29 patients with paired data available was analyzed, a significant reduction was found in the mean number of symptoms between baseline and 6 months ( $P < 0.0001$ ).

### Bilirubin reduction

The mean total bilirubin level at baseline was 10.7 mg/dL (standard deviation [SD] 9.4, range 0.5–38.0); this was reduced to 1.9 mg/dL (SD 2.2, range 0.1–12.0) at month 1. The mean bilirubin reduction on a per-patient basis was 73.1% (SD 27.5%, range 99.5%–50.0%) between baseline and month 1.

One study patient with recurrent biliary obstruction at day 35 did not have adequate reduction in total bilirubin at month 1.

### Time to recurrent biliary obstruction

Four patients experienced a recurrence of biliary obstruction after a mean of 110 days (SD 63, range 35–189). A Kaplan-Meier analysis based on the 66 evaluable patients (● Fig. 5) yielded an estimated re-obstruction rate at 6 months of 6.3% (SD 3.6%), which is close to the binary rate of 4 patients out of 66 (6.1%). The Kaplan-Meier curve extends beyond 180 days due to a 1-month allowable visit window for the 6-month visit.

### Stent repositioning and removability

Stents were repositioned in 3/69 of patients (4.3%). Two of these instances have already been described above in the sections on Safety and on Technical success. In the third patient the cystic duct remained filled with contrast after insertion of the study stent. The stent was pulled distally until the cystic duct drained and remained patent, with the intention of reducing the risk of cholecystitis (● Fig. 6).

Stent repositioning was successful in all three cases.

### Discussion

In this study, the partially covered nitinol biliary Wallflex stent provided adequate clinical palliation of biliary obstruction until the end of follow-up in 94% of patients. In addition, the goal of keeping patients out of hospital was also achieved, with few re-interventions for the treatment of recurrent biliary obstruction (4/66 patients). These numbers were similar to those in recent reports on the use of the PC Wallstent, which demonstrated patency at 6 months of 78% [14] and 93% [18].

Since the Wallstent was introduced in 1990 [10], biliary SEMSs have been shown to provide longer patency than plastic stents. Although some studies have shown cost-effectiveness of the SEMS compared with plastic stents in patients without distant metastases and >4 months of expected survival after initial stent placement [5–9], this is not universally true [19]. According to a recent meta-analysis [1] SEMS were associated with a reduced relative risk of stent occlusion at 4 months and a lower overall risk of recurrent biliary obstruction, when compared with plastic stents.

To overcome the problem of tissue ingrowth through the mesh of an uncovered SEMS, covered SEMSs were developed. Initially the covered SEMSs were not effective in preventing tumor ingrowth [20,21], while more recent covered SEMS devices have provided patency for longer periods than the uncovered SEMS [12–15]. In the present study, no tumor ingrowth was observed. This implies that the Permalume covering may resist degradation, remaining intact during the indwelling of the stent [22].

Covered SEMSs have a slightly higher incidence of stent migration compared with uncovered stents [13,14]. The two partial migrations seen in this prospective series explained the occurrence of cholangitis, and both were successfully retreated endoscopically. The retrieval loop of the PC biliary Wallflex is useful for acute removability and repositioning in a distal direction. In some cases of distal stent occlusion, drainage may be achieved by trimming the distal end of the stent by argon plasma coagulation [23] and subsequently placing another covered SEMS through the trimmed stent.

Acute cholecystitis is another potential complication of insertion of a covered SEMS, from impairment of cystic duct drainage. The reported incidence of cholecystitis following covered SEMS insertion ranges from 3% to 10% [13,14,24–26] but has not proven

significantly higher than that following uncovered SEMS insertion [25]. In the experience reported here with the PC biliary Wallflex, three patients developed acute cholecystitis, a rate consistent with published reports of cholecystitis incidence after SEMS placement.

Malignant non hilar biliary strictures are frequently a “C-curve.” In such cases, the proximal end of a SEMS with high linear tension can impact against the duct wall, leading to stent dysfunction. It is possible that more flexible metals such as nitinol minimize this risk as already suggested with Diamond stents [16]. Our experience with the new nitinol study stent confirmed the flexibility of the device, a feature which could account for the absence of dysfunction due to impaction of the proximal part of the stent.

Covered SEMSs have a potential advantage in patients with resectable tumors, especially if surgery is delayed or when patients receive several weeks of neoadjuvant chemoradiotherapy [27]. Surgical resection was shown to be possible in the presence of a SEMS [10,11], without increase in perioperative morbidity and mortality [10].

This study shows that the partially covered nitinol SEMS provides adequate palliation and duration of patency comparable with the best results in reported series of SEMS placement for palliation of malignant jaundice [14,18]. The features of this stent not only provide adequate palliation but also include acute removability.

### Acknowledgments

This trial was sponsored by Boston Scientific Corporation (Natick, Massachusetts, USA). The sponsor participated in planning and executing the study and in conducting data analysis. In this regard, principal contributions were made by Jeremy Bolt, Lina Ginnetti, Joy Peetermans PhD, medical monitor Robert S. Walsh MD, biostatistician John Evans PhD, and statistical programmer Wen Ding, all of Boston Scientific Corporation.

**Competing interests:** None

### Institutions

- <sup>1</sup> Università Cattolica del Sacro Cuore, Rome, Italy
- <sup>2</sup> Asian Institute of Gastroenterology, Hyderabad, India
- <sup>3</sup> Hospital Erasme, Université Libre de Bruxelles, Brussels, Belgium
- <sup>4</sup> Academic Medical Center, University of Amsterdam, Amsterdam, Netherlands
- <sup>5</sup> Hospital Edouard Herriot, Lyon, France
- <sup>6</sup> Medizinische Klinik, EVK Düsseldorf, Düsseldorf, Germany
- <sup>7</sup> Beth Israel Medical Center, New York, USA

### References

- 1 Moss AC, Morris E, Leyden J et al. Do the benefits of metal stents justify the costs? A systematic review and meta-analysis of trials comparing endoscopic stents for malignant biliary obstruction. *Eur J Gastroenterol Hepatol* 2007; 19: 1119–1124
- 2 Weber A, Mittermeyer T, Wagenpfeil S et al. Self-expanding metal stents versus polyethylene stents for palliative treatment in patients with advanced pancreatic cancer. *Pancreas* 2009; 38: e7–e12
- 3 Schmassmann A, von Gunten E, Knuchel J et al. Wallstents versus plastic stents in malignant biliary obstruction: effects of stent patency of the first and second stent on patient compliance and survival. *Am J Gastroenterol* 1996; 91: 654–659
- 4 Menon K, Romagnuolo J, Barkun AN. Expandable metal biliary stenting in patients with recurrent premature polyethylene stent occlusion. *Am J Gastroenterol* 2001; 96: 1435–1440



- 5 Yeoh KG, Zimmerman MJ, Cunningham JT *et al.* Comparative costs of metal versus plastic biliary stent strategies for malignant obstructive jaundice by decision analysis. *Gastrointest Endosc* 1999; 49: 466–471
- 6 Arguedas MR, Heudebert GH, Stinnett AA *et al.* Biliary stents in malignant obstructive jaundice due to pancreatic carcinoma: a cost-effectiveness analysis. *Am J Gastroenterol* 2002; 97: 898–904
- 7 Kaass M, Boyer J, Dumas R *et al.* Plastic or metal stents for malignant stricture of the common bile duct? Results of a randomized prospective study. *Gastrointest Endosc* 2003; 57: 178–182
- 8 Katsinelos P, Paikos D, Kountouras J *et al.* Tannenbaum and metal stents in the palliative treatment of malignant distal bile duct obstruction: a comparative study of patency and cost effectiveness. *Surg Endosc* 2006; 20: 1587–1593
- 9 Soderlund C, Linder S. Covered metal versus plastic stents for malignant common bile duct stenosis: a prospective, randomized, controlled trial. *Gastrointest Endosc* 2006; 63: 986–995
- 10 Davids PH, Groen AK, Rauws EA *et al.* Randomised trial of self-expanding metal stents versus polyethylene stents for distal malignant biliary obstruction. *Lancet* 1992; 340: 1488–1492
- 11 Bueno JT, Gerdes H, Kurtz RC. Endoscopic management of occluded biliary Wallstents: a cancer center experience. *Gastrointest Endosc* 2003; 58: 879–884
- 12 Isayama H, Komatsu Y, Tsujino T *et al.* Polyurethane-covered metal stent for management of distal malignant biliary obstruction. *Gastrointest Endosc* 2002; 55: 366–370
- 13 Isayama H, Komatsu Y, Tsujino T *et al.* A prospective randomised study of “covered” versus “uncovered” diamond stents for the management of distal malignant biliary obstruction. *Gut* 2004; 53: 729–734
- 14 Yoon WJ, Lee JK, Lee KH *et al.* A comparison of covered and uncovered Wallstents for the management of distal malignant biliary obstruction. *Gastrointest Endosc* 2006; 63: 996–1000
- 15 Han YM, Kwak HS, Jin GY *et al.* Treatment of malignant biliary obstruction with a PTFE-covered self-expandable nitinol stent. *Korean J Radiol* 2007; 8: 410–417
- 16 Dumonceau JM, Cremer M, Auroux J *et al.* A comparison of Ultraflex Diamond stent and Wallstent for palliation of distal malignant strictures. *Am J Gastroenterol* 2000; 95: 670–676
- 17 Shah RJ, Somogyi L, Petersen BT *et al.* Short-wire ERCP systems. *Gastrointest Endosc* 2007; 66: 650–657
- 18 Ornellas LC, Stefanidis G, Chuttani R *et al.* Covered Wallstents for palliation of malignant biliary obstruction: primary stent placement versus reintervention. *Gastrointest Endosc* 2009; 70: 676–683
- 19 Yoon WJ, Ryu JK, Yang KY *et al.* A comparison of metal and plastic stents for the relief of jaundice in unresectable malignant biliary obstruction in Korea: an emphasis on cost-effectiveness in a country with a low ERCP cost. *Gastrointest Endosc* 2009; 70: 284–289
- 20 Born P, Neuhaus H, Rösch T *et al.* Initial experience with a new, partially covered Wallstent for malignant biliary obstruction. *Endoscopy* 1996; 28: 699–702
- 21 Hausegger KA, Thurnher S, Bodendörfer G *et al.* Treatment of malignant biliary obstruction with polyurethane-covered Wallstents. *AJR Am J Roentgenol* 1998; 170: 403–408
- 22 Familiari P, Bulajic M, Mutignani M *et al.* Endoscopic removal of malfunctioning biliary self-expandable metallic stents. *Gastrointest Endosc* 2005; 62: 903–910
- 23 Christiaens P, Decock S, Buchel O *et al.* Endoscopic trimming of metallic stents with the use of argon plasma. *Gastrointest Endosc* 2008; 67: 369–371
- 24 Suk KT, Kim HS, Kim JW *et al.* Risk factors for cholecystitis after metal stent placement in malignant biliary obstruction. *Gastrointest Endosc* 2006; 64: 522–529
- 25 Isayama H, Kawabe T, Nakai Y *et al.* Cholecystitis after metallic stent placement in patients with malignant distal biliary obstruction. *Clin Gastroenterol Hepatol* 2006; 4: 1148–1153
- 26 Fumex F, Coumaros D, Napoleon B *et al.* Similar performance but higher cholecystitis rate with covered biliary stents: results from a prospective multicenter evaluation. *Endoscopy* 2006; 38: 787–792
- 27 Nakai Y, Isayama H, Kawabe T *et al.* Efficacy and safety of metallic stents in patients with unresectable pancreatic cancer receiving gemcitabine. *Pancreas* 2008; 37: 405–410