

EDITORIAL / *Technical*

High intensity focused ultrasound: Imaging is the key!

KEYWORDS

High intensity focused ultrasound ablation;
 Ablation techniques;
 MR guided interventional procedures;
 Ultrasonography;
 Interventional

High intensity focused ultrasound (HIFU) is a non-invasive medical technology for ablation of body tumors [1]. The fact that such treatment is done without the insertion of any needles into tumors, unlike radiofrequency (RF), cryotherapy or microwave ablation, attracted the attention of many physicians and scientists. However, for any medical technology to get fully integrated in clinical practice essential requirements need first to be fulfilled; namely: feasibility, efficacy and safety. HIFU has proved to be feasible and effective for treatment of body tumors. Many reports clearly showed significant clinical and laboratory improvement in patients treated by HIFU [2,3]. Treatment efficacy was not assessed only by medical imaging, but extended also to confirmation and characterization of the HIFU induced tissue damage on histology [3,4].

The “safety” issue in clinical practice usually refers to the concept of inducing no harm or unintended damage to surrounding structures. In this context, HIFU appears to be a safe technique for treatment of body tumors. In their study, to treat patients with hepatocellular carcinoma (HCC) adjacent to main hepatic blood vessels, Zhang et al. [5] reported the safety of HIFU therapy at a distance less than 1 cm from the portal vein, inferior vena cava (IVC) and their branches. When applied correctly, most of the complications associated with HIFU therapy are in the form of edema of the skin and subcutaneous tissue within the path of the HIFU beam. These events are frequently encountered and usually resolve spontaneously, therefore, they may not be considered a serious complication of HIFU therapy [6]. However, for evolving medical technologies like HIFU, especially in the field of oncology, the definition of “safety” entails other considerations. The ability to precisely monitor the treatment process is an essential safety determinant. Underestimation of the extent of ablation can mislead the treating physician, getting him to spend more time trying to ablate tissues that are already ablated. This leads to the prolongation of the already known lengthy HIFU ablation sessions, and may lead to overheating that increases the incidence of accidental injury of nearby vital structures. On the other hand, false overestimation of the extent of ablation will leave the physician comfortable that the whole tumor was ablated, while in fact it was not. This will be translated clinically into residual viable tumoral tissue in later follow-up.

To help solving this dilemma, it is important to understand how and why this problem is more distinct with HIFU than with any other ablation technique. It is also helpful to understand how imaging can bring in answers for such a problem. Taking RF ablation as an example, during ablation, treating physicians get instantaneous feedback regarding changes in tissue impedance and local temperature rise in vicinity of the tip of the RF needle. Analysis of these data gets physicians assured that satisfactory tissue ablation was achieved. However, with HIFU nothing is inserted inside the tumor, and this calls for advanced feedback mechanisms to evaluate the ablation at the focus. Here comes the unique role that medical imaging has to play as regards to HIFU therapy.

Magnetic resonance imaging (MRI) and ultrasound are currently used to monitor HIFU therapy. MRI makes use of changes in the proton resonance frequency (PRF) in response to tissue heating to convey information regarding temperature changes at the focus. Shifts in PRF were found to correlate, in most cases, with temperature rise at the focus (sensitive for increments of about 1 °C) [7]. Thus, it was possible to translate these PRF shifts into thermal maps that can track focal temperature rise and gives clinically accepted indicators that sufficient thermal dose has been delivered to ablate the tissue at the focus. In addition to the high-resolution imaging that MRI provides, we believe that MR thermometry was one of the main factors that contributed for the US Food and Drug Administration (FDA) approval of the only two FDA approved clinical HIFU applications so far: ablation of uterine fibroids and pain palliation from bone metastasis. Though the concept is validated and already in clinical use; some limitations still exist. Thermal maps are degraded by respiratory movements and are not that efficient to track temperature changes in fat [7,8].

On the other side, ultrasound in current clinical systems appears to be defective in tracking the lethal temperature elevation in tissues, due to the absence of clinical ultrasound thermometry so far. Instead, ultrasound monitoring uses changes in echogenicity at the focus, in the form of hyper-echogenic changes, as an indication of tissue damage. However, the exact mechanism by how these hyper-echogenic changes develop is still questionable. The most acceptable explanation is that these changes reflect bubble activity rather than mere thermal tissue ablation [7]. This may explain why these echogenic changes are usually transient in nature. Moreover, in some conditions the hyper-echogenic changes may be absent, hardly appreciable or even relatively delayed, reflecting the fact that such echogenic changes may indicate cavitation activity rather than only coagulative necrosis [7,9]. In such cases, the echogenic changes may overestimate the size of the HIFU lesion and can be pre-focal in location. Some informative studies were published correlating the extent of these echogenic changes to the extent of tissue ablation, as inferred from follow-up MRI imaging and histology [4,10]. We may share the idea that hyper-echogenic changes can be used to indicate and localize tissue damage. However, we

strongly believe that further research is still needed before dogmatic statements can be made regarding the accuracy of using these echogenic changes to precisely estimate the size and extent of actual tissue ablation.

In view of the aforementioned facts and discussion, an important question comes now on the scene: which is better in clinical practice: MRI or ultrasound guided HIFU? Ironically, though the differences between MRI and ultrasound guidance are well known (Table 1), no clear answer is available in literature despite the importance of the question! We think the lack of a definitive answer may be attributed to the fact that no one really has the "right" one. In our opinion, the "scientific" answer to such a question should come through well-designed comparative studies. However, to our knowledge and in our opinion, such studies are not currently available and will not be available soon, since most of the current research work is directed to validate the efficacy of HIFU for clinical applications rather than to compare the guidance methods. In our opinion, two main factors determine which imaging method is the best. The first is the HIFU application itself; and the second is the experience of the operating physicians. Taking liver tumors as an example, ultrasound guided HIFU has the upper hand so far because high-resolution real-time imaging can be obtained despite respiratory movements. Such movements may degrade MRI imaging. Though some ideas are proposed on the MRI side to overcome this problem [8,11], straightforward analysis of the literature reveals that the vast majority of hepatic interventions were done using the ultrasound guided machines.

Another good example of an ultrasound guided HIFU application is the treatment of prostate cancer. The treatment has been conducted for long time under ultrasound guidance and monitoring, with thousands of patients being treated by HIFU either as a salvage treatment after radiotherapy [12] or in the form of whole gland ablation for localized prostate cancer [13]. Recently, MRI guidance was introduced for ablation of prostate cancer [14], however, the numbers of patients treated under MRI guidance are still much lower than those treated under ultrasound guidance.

On the other hand, other applications are more suitable for MRI guided HIFU. Investigational treatment of essential tremors, Parkinsonism and neuropathic pain through intact skull bone is exclusively done under MRI guidance.

Table 1 Main differences between magnetic resonance and ultrasound imaging guidance.

Guidance	MRI	Ultrasound
Advantages	High soft tissue resolution and tumor characterization	Real-time imaging not degraded by respiratory movement
Treatment monitoring	MRI thermometry: changes in PRF correlates with localized heating	Hyper-echogenic changes reflecting cavitation activity at the focus
Limitations	Temperature maps are not that accurate in fat and are degraded by respiratory movements	Echogenic changes may be delayed or even pre-focal in location
Cost-effectiveness	More expensive	Relatively less expensive
FDA approval	Approved for ablation of uterine fibroids and for bone metastasis	Not yet approved
Main applications	Uterine fibroids, bone metastasis and investigational neurosurgery applications	Liver, pancreas and prostate tumors as well as uterine fibroids

MRI: Magnetic resonance imaging; PRF: proton resonance frequency; FDA: Food and Drug Administration.

Palliation of pain from bone metastasis is also more convenient under MRI guidance, owing to the high-resolution MR imaging of bone and nearby neurovascular bundle as compared to ultrasound [8]. In between both extremes come some other applications, like treatment of uterine fibroids that can be done under MRI or ultrasound guidance; with satisfactory clinical outcomes [15,16].

Secondly, in oncology, physicians are more comfortable with MRI than with other imaging modalities. However, clinical outcomes published in literature regarding treatments of tumors using ultrasound guided HIFU are indeed impressive (Fig. 1). These studies come mostly from places where ultrasound guided HIFU is widely used, like China for hepatic tumors [2,3] and France for prostate cancer ablation [12,13]. This highlights the fact that local experience with the available systems is an important determinant factor for which guidance method is more convenient or preferred. The lack of ultrasound thermometry in clinical practice so far is an important factor that gives an advantage for MRI guidance, while the relative low cost of ultrasound guidance, as compared to MRI, is in favor of ultrasound guided systems.

The early reports for clinical application of HIFU date back to the 1950s. However, owing to lack of satisfactory imaging to guide and monitor the treatment, HIFU remained in a dark cave for more than 40 years! In the second half of the 1990s, there was a rediscovery of HIFU for clinical

applications, thanks to the availability of MRI and high-resolution ultrasound imaging. Nowadays, ambitious research work is conducted to provide faster multi-reference MRI temperature imaging and motion tracking techniques to overcome the artifacts caused by respiratory movements [8]. Furthermore, MRI thermometry is investigated to provide an instantaneous feedback to control the sonication power, in a way that allows for delivery of enough power to induce thermal ablation without wasting extra time or energy for unnecessary overheating. This technology is expected to reduce the treatment time of MRI guided HIFU therapy [8,17].

Other feedback criteria from ultrasound imaging, like elastography and changes in speed of sound secondary to local temperature elevation [7], are investigated to provide additional feedback regarding the focal thermal ablation rather than depending only on the hyper-echogenic changes. In view of all this research work, we are optimistic that medical imaging will provide the adequate and necessary feedback for successful HIFU therapy.

HIFU has proved itself as a feasible, efficient and clinically safe technology for ablation of body tumors. Nowadays, what is needed from medical imaging is not only to see what is going on at the focus, but also to accurately *quantify* the extent of the induced damage. This may be the hardest challenge ever for medical imaging as regards HIFU.

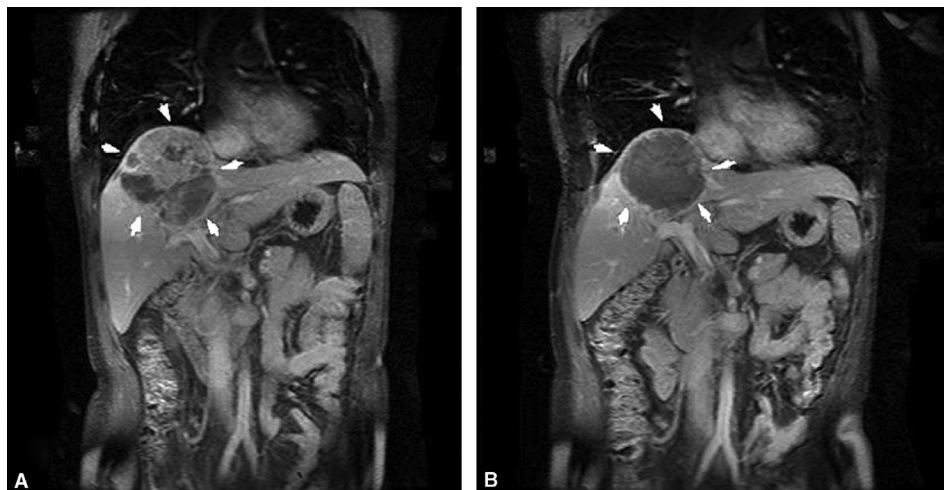


Figure 1. Post-contrast coronal MRI of a hepatic tumor treated by ultrasound guided HIFU [1]. A. Right hepatic lobe tumor showing heterogenous contrast enhancement before treatment. B. After HIFU therapy, no significant enhancement is seen denoting adequate tumor ablation.

(Photo courtesy: Dr. Hui Zhu) (re-printed with permission from Elsevier).

Disclosure of interest

The author declares that he has no conflicts of interest concerning this article.

References

- [1] Shehata IA. Treatment with high intensity focused ultrasound: secrets revealed. *Eur J Radiol* 2012;81:534–41.
- [2] Wu F, Wang ZB, Chen WZ, Zhu H, Bai J, Zou JZ, et al. Extracorporeal high intensity focused ultrasound ablation in the treatment of patients with large hepatocellular carcinoma. *Ann Surg Oncol* 2004;11:1061–9.
- [3] Wu F, Wang ZB, Chen WZ, Wang W, Gui Y, Zhang M, et al. Extracorporeal high intensity focused ultrasound ablation in the treatment of 1038 patients with solid carcinomas in China: an overview. *Ultrason Sonochem* 2004;11:149–54.
- [4] Leslie TA, Kennedy JE, Illing RO, Ter Haar GR, Wu F, Phillips RR, et al. High-intensity focused ultrasound ablation of liver tumours: can radiological assessment predict the histological response? *Br J Radiol* 2008;81:564–71.
- [5] Zhang L, Zhu H, Jin C, Zhou K, Li K, Su H, et al. High-intensity focused ultrasound (HIFU): effective and safe therapy for hepatocellular carcinoma adjacent to major hepatic veins. *Eur Radiol* 2009;9:437–45.
- [6] Shehata IA. High intensity focused ultrasound (HIFU): call for careful patient selection! *Abdom imaging* 2012;38:419–20.
- [7] Zhou YF. High intensity focused ultrasound in clinical tumor ablation. *World J Clin Oncol* 2011;2:8–27.
- [8] Hynynen K. MRigHIFU: a tool for image-guided therapeutics. *J Magn Reson Imaging* 2011;34:482–93.
- [9] Rabkin BA, Zderic V, Crum LA, Vaezy S. Biological and physical mechanisms of HIFU-induced hyper-echo in ultrasound images. *Ultrasound Med Biol* 2006;32:1721–9.
- [10] Leslie T, Ritchie R, Illing R, Ter Haar G, Phillips R, Middleton M, et al. High-intensity focused ultrasound treatment of liver tumours: post-treatment MRI correlates well with intra-operative estimates of treatment volume. *Br J Radiol* 2012;85:1363–70.
- [11] de Zwart JA, Vimeux FC, Palussière J, Salomir R, Quesson B, Delalande C, et al. On-line correction and visualization of motion during MRI-controlled hyperthermia. *Magn Reson Med* 2001;45:128–37.
- [12] Murat FJ, Poissonnier L, Rabilloud M, Belot A, Bouvier R, Rouviere O, et al. Mid-term results demonstrate salvage high-intensity focused ultrasound (HIFU) as an effective and acceptably morbid salvage treatment option for locally radiorecurrent prostate cancer. *Eur Urol* 2009;55:640–7.
- [13] Crouzet S, Chapelon JY, Rouvière O, Mege-Lechevallier F, Colombel M, Tonoli-Catez H, et al. Whole-gland ablation of localized prostate cancer with high-intensity focused ultrasound: oncologic outcomes and morbidity in 1002 patients. *Eur Urol* 2013, <http://dx.doi.org/10.1016/j.eururo.2013.04.039>.
- [14] Zini C, Hipp E, Thomas S, Napoli A, Catalano C, Oto A. Ultrasound- and MR-guided focused ultrasound surgery for prostate cancer. *World J Radiol* 2012;4:247–52.
- [15] Kamp JE, David M, Scheurig-Muenkler C, Hengst S, Beck A. Clinical outcome of magnetic-resonance-guided focused ultrasound surgery (MRgFUS) in the treatment of symptomatic uterine fibroids. *ROFO* 2013;185:136–43.
- [16] Zhao WP, Chen JY, Zhang L, Li Q, Qin J, Peng S, et al. Feasibility of ultrasound-guided high intensity focused ultrasound ablating uterine fibroids with hyperintense on T2-weighted MR imaging. *Eur J Radiol* 2013;82:e43–9.
- [17] Shehata IA, Al-Azizy HM, Saeed AS. High intensity focused ultrasound (HIFU): scalpel-free surgery at last? *DI Europe* 2012;28:29–32.

I.A. Shehata*

Department of Diagnostic and Interventional Radiology, Scientific Research Unit, Kasr Al-Ainy Faculty of Medicine, Cairo University, Cairo, Egypt

* Correspondence. Department of Diagnostic and Interventional Radiology, Kasr Al-Ainy Faculty of Medicine, Cairo University, Elmanyal, Cairo, Egypt.
E-mail address: islamhifu@gmail.com